



© AGO e. V.  
in der DGGG e.V.  
sowie  
in der DKG e.V.


Guidelines Breast  
Version 2024.1E

FORSCHEN  
LEHREN  
HEILEN

# Diagnosis and Treatment of Patients with early and advanced Breast Cancer

## Lesions of Uncertain Malignant Potential (B3)

(ADH, LIN, FEA, Papilloma, Radial Scar/Complex Sclerosing  
Lesion)



## Lesions of Uncertain Malignant Potential (B3)

### Versionen 2005–2023:

Albert / Audretsch / Bauerfeind / Brunnert / Ditsch / Fallenberg / Fersis /  
Friedrich / Friedrichs / Gerber / Huober / Kolberg-Liedtke / Kreipe /  
Maass / Nitz / Reimer / Rody / Schmidt / Schreer / Sinn / Thomssen

### Version 2024:

Friedrich / Sinn

### Pubmed 2010-2023 queries

#### Lobular neoplasia (169 Results)

(Breast Diseases/CL[mh] OR Breast Diseases/DI[mh] OR Breast Diseases/EP[mh] OR Breast Diseases/GE[mh] OR Breast Diseases/MO[mh] OR Breast Diseases/PA[mh] OR Breast Diseases/RT[mh] OR Breast Diseases/SU[mh] OR Breast Diseases/TH[mh]) AND ("2012/01/01"[dp] : "2023/01/01"[dp]) AND ("lobular neoplasia"[ti] OR "lobular intraepithelial neoplasia"[ti] OR "atypical lobular hyperplasia"[ti] OR "lobular carcinoma in situ"[ti] OR "LIN"[ti] OR "ALH"[ti] OR "LCIS"[ti]) AND ("english"[la] OR "german"[la])

#### Atypical ductal hyperplasia (101 Results)

(Breast Diseases/CL[mh] OR Breast Diseases/DI[mh] OR Breast Diseases/EP[mh] OR Breast Diseases/GE[mh] OR Breast Diseases/MO[mh] OR Breast Diseases/PA[mh] OR Breast Diseases/RT[mh] OR Breast Diseases/SU[mh] OR Breast Diseases/TH[mh]) AND ("2012/01/01"[dp] : "2023/01/01"[dp]) AND ("atypical ductal hyperplasia"[ti] OR "atypical hyperplasia"[ti] OR "ADH"[ti]) AND ("english"[la] OR "german"[la])

#### Flat epithelial atypia (59 Results)

(Breast Diseases/CL[mh] OR Breast Diseases/DI[mh] OR Breast Diseases/EP[mh] OR Breast Diseases/GE[mh] OR Breast Diseases/MO[mh] OR Breast Diseases/PA[mh] OR Breast Diseases/RT[mh] OR Breast Diseases/SU[mh] OR Breast Diseases/TH[mh])

AND ("2012/01/01"[dp] : "2023/01/01"[dp]) AND ("flat epithelial atypia"[ti] OR "columnar cell"[ti] OR "FEA"[ti]) AND ("english"[la] OR "german"[la])

Papilloma (278 Results)

(Breast Diseases/CL[mh] OR Breast Diseases/DI[mh] OR Breast Diseases/EP[mh] OR Breast Diseases/GE[mh] OR Breast Diseases/MO[mh] OR Breast Diseases/PA[mh] OR Breast Diseases/RT[mh] OR Breast Diseases/SU[mh] OR Breast Diseases/TH[mh]) AND ("2012/01/01"[dp] : "2023/01/01"[dp]) AND ("papilloma"[ti] OR "papillary"[ti]) AND ("english"[la] OR "german"[la]) NOT virus[ti]


Radial scar (25 Results)

(Breast Diseases/CL[mh] OR Breast Diseases/DI[mh] OR Breast Diseases/EP[mh] OR Breast Diseases/GE[mh] OR Breast Diseases/MO[mh] OR Breast Diseases/PA[mh] OR Breast Diseases/RT[mh] OR Breast Diseases/SU[mh] OR Breast Diseases/TH[mh]) AND ("2012/01/01"[dp] : "2023/01/01"[dp]) AND ("radial scar"[ti] OR "complex sclerosing lesion"[ti] OR "radial sclerosing lesion"[ti]) AND ("english"[la] OR "german"[la])

#### National and international guidelines

1. AWMF, Deutschen Krebsgesellschaft e.V. und Deutschen Krebshilfe e.V. (Hrsg.). Interdisziplinäre S3-Leitlinie für die Diagnostik, Therapie und Nachsorge des Mammakarzinoms. Langversion 4.0, Aktualisierung 2021 <http://www.leitlinienprogramm-onkologie.de/leitlinien/mammakarzinom/>
2. National Comprehensive Cancer Network. NCCN Clinical Practice Guidelines in Oncology. Breast cancer. Version 1. 2020.
3. National Comprehensive Cancer Network (NCCN). Breast Cancer Screening and Diagnosis. Version 1.2019
4. Rageth CJ, O'Flynn EAM, Pinker K, et al. Second International Consensus Conference on lesions of uncertain malignant potential in the breast (B3 lesions). Breast Cancer Res Treat. 2019 Apr;174(2):279–96.
5. Scottish Intercollegiate Guidelines Network (SIGN) (2013) SIGN 134 • Treatment of primary breast cancer. <http://www.sign.ac.uk/pdf/SIGN134.pdf>
6. World Health Organization: WHO Classification of Tumours of the Breast. Lokuhetty D, White VA, Watanabe R, Cree IA (Hrsg.) 2019.
7. American Society of Breast Surgeons: Consensus Guideline on Concordance Assessment of Image-Guided Breast Biopsies and Management of Borderline or High-Risk Lesions, 2016 <https://www.breastsurgeons.org/docs/statements/Consensus-Guideline-on->

Concordance-Assessment-of-Image-Guided-Breast-Biopsies.pdf?v2




# Pathology Reporting for Minimal Invasive Biopsies

## B-Classification\*

- B1 = Unsatisfactory or normal tissue only**
- B2 = Benign lesion**
- B3 = Lesion of uncertain malignant potential**
- B4 = Suspicion of malignancy**
- B5 = Malignant**
  - B5a = Non-invasive
  - B5b = Invasive
  - B5c = In situ / invasion not assessable
  - B5d = Non epithelial, metastatic

\* AWMF, Deutschen Krebsgesellschaft e.V. und Deutschen Krebshilfe e.V. (Hrsg.). Interdisziplinäre S3-Leitlinie für die Diagnostik, Therapie und Nachsorge des Mammakarzinoms. Langversion 4.4, Juni 2021


1. The Royal College of Pathologists. Guidelines for non-operative diagnostic procedures and reporting in breast cancer [Internet]. United Kingdom: National ...; 2021. Available from: <https://www.rcpath.org/profession/publications/cancer-datasets.html>
2. Ellis IO, Humphreys S, Michell M et al. Best Practice No 179. Guidelines for breast needle core biopsy handling and reporting in breast screening assessment. Vol. 57, Journal of clinical pathology. 2004. pp. 897–902.
3. Wells C (ed.) (2006) Quality assurance guidelines for pathology: Cytological and histological non-operative procedures. In: European guidelines for quality assurance in breast cancer screening and diagnosis. Perry N, Broeders M, de Wolf C, Törnberg S, Holland R, Koch von F, editors. Luxembourg: Office for Official Publications of the European Communities, ISBN 92-79-01258-4 pp. 221-256 Retrieved from <http://www.euref.org/european-guidelines>
4. Wells, C. A. (2014). Pathology Update Breast Screening, pp. 1 - 48. Retrieved from <http://www.euref.org/european-guidelines>
5. World Health Organization: WHO Classification of Tumours of the Breast. Lokuhetty D, White VA, Watanabe R, Cree IA (Hrsg.) 2019.



© AGO e. V.  
in der DGGG e.V.  
sowie  
in der DKG e.V.

Guidelines Breast  
Version 2024.1D

www.ago-online.de



## B3-Lesions

---

- 1. Lesions with increased risk of associated DCIS or invasive carcinoma**
  - Atypical ductal hyperplasia (ADH) or atypical epithelial proliferation of ductal type (classification possibly as B4, depending on extent of lesion)
  - Flat epithelial atypia (FEA)
  - Lobular neoplasia (LIN; LN; now subdivided into ALH and LCIS, no differentiation according to older nomenclature) classical and non-classical type
  - Atypical apocrine adenosis
- 2. Potentially heterogeneous lesions with risk of incomplete sampling**
  - Cellular fibroepithelial lesion or phyllodes tumour without evidence of malignancy
  - Intraductal papilloma with / without atypia (possibly also B4, depending on the extent of the lesion)
  - Radial scar or complex sclerosing lesion (unless the radial scar only microscopically, not radiologically detected: B2)
  - Hemangioma
- 3. Rare Lesions**
  - Adenomyoepithelioma, nipple adenoma, microglandular adenosis, mucocele-like lesion, nodular fasciitis, desmoid-type fibromatosis, spindle cell lesion of unknown significance

1. The Royal College of Pathologists. Guidelines for non-operative diagnostic procedures and reporting in breast cancer [Internet]. United Kingdom: National ...; 2016. Available from: <https://www.rcpath.org/profession/publications/cancer-datasets.html>
2. Ellis IO, Humphreys S, Michell M et al. Best Practice No 179. Guidelines for breast needle core biopsy handling and reporting in breast screening assessment. Journal of clinical pathology. 2004; 57: 897–902.
3. Wells C (ed.) (2006) Quality assurance guidelines for pathology: Cytological and histological non-operative procedures. In: European guidelines for quality assurance in breast cancer screening and diagnosis. Perry N, Broeders M, de Wolf C, Törnberg S, Holland R, Koch von F, editors. Luxembourg: Office for Official Publications of the European Communities, ISBN 92-79-01258-4 pp. 221-256 Retrieved from <http://www.euref.org/european-guidelines>
4. Wells, C. A. (2014). Pathology Update Breast Screening, pp. 1 - 48. Retrieved from <http://www.euref.org/european-guidelines>
5. World Health Organization: WHO Classification of Tumours of the Breast. Lokuhetty D, White VA, Watanabe R, Cree IA (Hrsg.) 2019.

## Management after Minimally Invasive Biopsy

	Oxford		
	LoE	GR	AGO
<ul style="list-style-type: none"> <li>Interdisciplinary conference: Concordant findings in pathology and imaging?           <ul style="list-style-type: none"> <li>yes: proceed according to histologic type and dimension of lesion</li> <li>no: open biopsy</li> </ul> </li> </ul>			
Vacuum-assisted biopsy (after core biopsy)	3a	C	++
	3a	C	++
	5	D	+

- Atkins KA, Cohen MA, Nicholson B et al.: Atypical lobular hyperplasia and lobular carcinoma in situ at core breast biopsy: use of careful radiologic-pathologic correlation to recommend excision or observation. *Radiology*. 2013 Nov;269(2):340-7.
- AWMF, Deutschen Krebsgesellschaft e.V. und Deutschen Krebshilfe e.V. (Hrsg.). Interdisziplinäre S3-Leitlinie für die Diagnostik, Therapie und Nachsorge des Mammakarzinoms. Langversion 4.0, Aktualisierung 2021 <http://www.leitlinienprogramm-onkologie.de/leitlinien/mammakarzinom/>
- Calhoun, B. C., & Collins, L. C. (2016). Recommendations for excision following core needle biopsy of the breast: a contemporary evaluation of the literature. *Histopathology*, 68(1), 138–151. <http://doi.org/10.1111/his.12852>
- Hayes BD, O'Doherty A, Quinn CM. Correlation of needle core biopsy with excision histology in screen-detected B3 lesions: the Merrion Breast Screening Unit experience. *J Clin Pathol*. 2009 Dec 1;62(12):1136–40.
- Houssami N et al: Borderline breast core needle histology: predictive values for malignancy in lesions of uncertain malignant potential (B3). *Br J Cancer* 2007; 96:1253-1257
- Middleton LP, Sneige N, Coyne R et al.: Most lobular carcinoma in situ and atypical lobular hyperplasia diagnosed on core needle biopsy can be managed clinically with radiologic follow-up in a multidisciplinary setting. *Cancer Med*. 2014 Jun;3(3):492-9
- Morrow, M., Schnitt, S. J., & Norton, L. (2015). Current management of lesions associated with an increased risk of breast cancer. *Nature Reviews. Clinical Oncology*, 12(4), 227–238. <http://doi.org/10.1038/nrclinonc.2015.8>
- Neal L, Sandhu NP, Hieken TJ et al.: Diagnosis and management of benign, atypical, and indeterminate breast lesions detected on

core needle biopsy. *Mayo Clin Proc.* 2014 Apr;89(4):536-47

9. Rageth CJ, O'Flynn EA, Comstock C et al. First International Consensus Conference on lesions of uncertain malignant potential in the breast (B3 lesions). *Breast Cancer Res Treat.* Springer US; 2016 Sep;159(2):203–13.
10. Saladin C, Haueisen H, Kampmann G et al. Lesions with unclear malignant potential (B3) after minimally invasive breast biopsy: evaluation of vacuum biopsies performed in Switzerland and recommended further management. *Acta Radiol.* 2016 Jul;57(7):815–21.
11. Sinn HP, Flechtenmacher C, Aulmann S. Diagnostik benigner duktaler Epithelproliferationen der Mamma in der Stanzbiopsie. *Der Pathologe.* Springer Berlin Heidelberg; 2014 Feb;35(1):18–25.
12. Thomas PS. Diagnosis and Management of High-Risk Breast Lesions. *J Natl Compr Canc Netw.* 2018 Nov;16(11):1391–6. *Mod Pathol*



## Strategy after Diagnosis of ADH in Biopsy Specimen

	Oxford		
	LoE	GR	AGO
<b>ADH in core- / vacuum-assisted biopsy:</b>			
▪ <b>Open excisional biopsy</b>	3a	C	++
▪ <b>Open excisional biopsy may be omitted, if all following requirements apply:</b>	5	C	+/-
a) No mass-lesion radiologically, and			
b) a small lesion ( $\leq 2$ TDLU*) in vacuum biopsy, and			
c) complete removal of imaging abnormality			
<b>ADH at margins in open biopsy specimen:</b>			
▪ <b>No further surgery, if incidental finding accompanies invasive or intraductal carcinoma</b>	3a	C	+

\* Terminal ductal-lobular unit

1. Sanders, M. E. & Podoll, M. B. Atypical Ductal Hyperplasia-Ductal Carcinoma In Situ Spectrum: Diagnostic Considerations and Treatment Impact in the Era of Deescalation. *Surg Pathology Clin* **15**, 95–103 (2022).
2. Kilgore, L. J. *et al.* Risk of Breast Cancer in Selected Women With Atypical Ductal Hyperplasia Who do not Undergo Surgical Excision. *Ann Surg* **276**, e932–e936 (2022).
3. Sanharawi, I. E. *et al.* Clinical management of atypical ductal hyperplasia on vacuum-assisted biopsy of microcalcifications: External validation study of a decision tree selecting patients eligible for surveillance. *Eur J Radiol* **141**, 109826 (2021).
4. Gagnon, N. *et al.* Upgrade rate of atypical ductal hyperplasia: ten years experience and predictive factors. *J Surg Res* **266**, 311–318 (2021).
5. Schiaffino, S., Cozzi, A. & Sardanelli, F. An update on the management of breast atypical ductal hyperplasia. *Br J Radiology* **93**, 20200117 (2020).
6. Lewin, A. A. & Mercado, C. L. Atypical Ductal Hyperplasia and Lobular Neoplasia: Update and Easing of Guidelines. *American Journal of Roentgenology* **214**, 265–275 (2020).
7. Amin, A. L., Fan, F., Winblad, O. D., Larson, K. E. & Wagner, J. L. Ipsilateral and Concurrent Breast Cancer and Atypical Ductal Hyperplasia: Does Atypia Also Need Surgical Excision? *Ann Surg Oncol* **27**, 4786–4794 (2020).
8. Rageth, C. J. *et al.* Atypical ductal hyperplasia and the risk of underestimation: tissue sampling method, multifocality, and associated calcification significantly influence the diagnostic upgrade rate based on subsequent surgical specimens. *Breast Cancer* **26**, 452–458

(2019).

9. Sutton, T., Farinola, M., Johnson, N. & Garreau, J. R. Atypical ductal hyperplasia: Clinicopathologic factors are not predictive of upgrade after excisional biopsy. *American journal of surgery* **217**, 848–850 (2019).
10. Weiss, J. B. *et al.* Is bigger better? Twenty-year institutional experience of atypical ductal hyperplasia discovered by core needle biopsy. *American journal of surgery* **217**, 906–909 (2019).
11. Farshid, G., Edwards, S., Kollias, J. & Gill, P. G. Active surveillance of women diagnosed with atypical ductal hyperplasia on core needle biopsy may spare many women potentially unnecessary surgery, but at the risk of undertreatment for a minority: 10-year surgical outcomes of 114 consecutive cases from a single center. *Modern Pathology* **31**, 395–405 (2018).
12. Racz, J. M. & Degnim, A. C. When Does Atypical Ductal Hyperplasia Require Surgical Excision? *Surgical oncology clinics of North America* **27**, 23–32 (2018).



© AGO e. V.  
in der DGGG e.V.  
sowie  
in der DKG e.V.

Guidelines Breast  
Version 2024.1E

www.ago-online.de

FORSCHEN  
LEBEN  
HEILEN

## Lobular Intraepithelial Neoplasia (LIN / LCIS)

- Includes:
  - Atypical lobular hyperplasia
  - Classical lobular carcinoma in situ (LIN, classical variant)
  - Non-Classical lobular carcinoma in situ (LIN, classical variant)
- LIN 1–3 classification is not sufficiently validated prognostically
- Non-Classical LIN (pleomorphic LIN, florid LIN) are classified as lesions with elevated risk → potentially **B5a**
- Indicator / precursor lesion:  
Ipsi- and contralaterally increased breast cancer risk:  
7x after 10 years

1. Calhoun, B. C. & Collins, L. C. Recommendations for excision following core needle biopsy of the breast: a contemporary evaluation of the literature. *Histopathology* **68**, 138–151 (2016).
2. Pravettoni, G. *et al.* Eliminating “ductal carcinoma in situ” and “lobular carcinoma in situ” (DCIS and LCIS) terminology in clinical breast practice: The cognitive psychology point of view. *Breast (Edinburgh, Scotland)* **25**, 82–85 (2016).
3. Ginter, P. S. & D’Alfonso, T. M. Current Concepts in Diagnosis, Molecular Features, and Management of Lobular Carcinoma In Situ of the Breast With a Discussion of Morphologic Variants. *Archives of Pathology & Laboratory Medicine* **141**, 1668–1678 (2017).
4. Wen, H. Y. & Brogi, E. Lobular Carcinoma In Situ. *Surgical pathology clinics* **11**, 123–145 (2018).
5. Pinder, S. E. & Shaaban, A. M. In situ lobular proliferations of the breast. *Diagnostic Histopathology* **24**, 58–63 (2018).
6. Calle, C., Kuba, M. G. & Brogi, E. Non-invasive lobular neoplasia of the breast: Morphologic features, clinical presentation, and management dilemmas. *Breast J* **26**, 1148–1155 (2020).
7. Schnitt, S. J., Brogi, E., Chen, Y.-Y., King, T. A. & Lakhani, S. R. American Registry of Pathology Expert Opinions: The Spectrum of Lobular Carcinoma in Situ: Diagnostic Features and Clinical Implications. *Ann Diagn Pathol* **45**, 151481 (2020).
8. Brogi, E. The morphologic spectrum of lobular carcinoma in situ (LCIS) observations on clinical significance, management implications and diagnostic pitfalls of classic, florid and pleomorphic LCIS. *Virchows Arch* **481**, 823–837 (2022).



© AGO e. V.  
in der DGGG e.V.  
sowie  
in der DKG e.V.

Guidelines Breast  
Version 2024.1E

www.ago-online.de

FORSCHEN  
LEBEN  
HEILEN

## Upgrade rates\* for B3 lesions

\* i.e., upgrade to malignant diagnosis when excised

Risk lesion	Upgrade rate to in situ or invasive Ca	References
Atypical lobular hyperplasia (ALH)	5%	[1]
Classical lobular neoplasia (C-LCIS)	4 - 16%	[1-3]
Non-classical lobular neoplasia (pleomorphic, florid LCIS, NC-LCIS)	33 - 39%	[3, 4]
Atypical ductal hyperplasia (ADH)	23%	[1]
Flat epithelial atypia (FEA)	0 - 14%	[5, 6]
Papilloma	12%	[7]
- no atypia	6 - 10%	[7, 8]
- atypia	21 -29%	[8, 9]
Radial scar or complex sclerosing lesion	7 - 11%	[10-12]
- no atypia	5%	[12]
- atypia	25%	[13]

1. Lewin AA, Mercado CL. Atypical Ductal Hyperplasia and Lobular Neoplasia: Update and Easing of Guidelines. AJR Am J Roentgenol. 2020;214(2):265-75. doi: 10.2214/AJR.19.21991.
2. Singh K, Sung CJ, Quddus MR. Descriptive study comparing outcomes of classic and nonclassic lobular carcinoma in situ (florid and pleomorphic) initially diagnosed on core needle biopsy. Breast J. 2020;26(12):2350-6. doi: 10.1111/tbj.14085.
3. Shamir ER, Chen YY, Chu T, Pekmezci M, Rabban JT, Krings G. Pleomorphic and Florid Lobular Carcinoma In Situ Variants of the Breast: A Clinicopathologic Study of 85 Cases With and Without Invasive Carcinoma From a Single Academic Center. Am J Surg Pathol. 2019;43(3):399-408. doi: 10.1097/PAS.0000000000001191.
4. Schnitt SJ, Brogi E, Chen YY, King TA, Lakhani SR. American Registry of Pathology Expert Opinions: The Spectrum of Lobular Carcinoma in Situ: Diagnostic Features and Clinical Implications. Ann Diagn Pathol. 2020;45:151481. doi: 10.1016/j.anndiagpath.2020.151481.
5. Wahab RA, Lee SJ, Mulligan ME, Zhang B, Mahoney MC. Upgrade Rate of Pure Flat Epithelial Atypia Diagnosed at Core Needle Biopsy: A Systematic Review and Meta-Analysis. Radiol Imaging Cancer. 2021;3(1):e200116. doi: 10.1148/rycan.2021200116.
6. Calhoun BC, Sobel A, White RL, Gromet M, Flippo T, Sarantou T, et al. Management of flat epithelial atypia on breast core biopsy may be individualized based on correlation with imaging studies. Mod Pathol. 2015;28(5):670-6. doi: 10.1038/modpathol.2014.159.
7. MacColl C, Salehi A, Parpia S, Hodgson N, Ramonas M, Williams P. Benign breast papillary lesions diagnosed on core biopsy: upgrade rate and risk factors associated with malignancy on surgical excision. Virchows Arch. 2019;475(6):701-7. doi: 10.1007/s00428-019-

02626-5.

8. Khan S, Diaz A, Archer KJ, Lehman RR, Mullins T, Cardenosa G, et al. Papillary lesions of the breast: To excise or observe? *Breast J.* 2018;24(3):350-5. doi: 10.1111/tbj.12907.
9. Nakhlis F, Ahmadiyah N, Lester S, Raza S, Lotfi P, Golshan M. Papilloma on core biopsy: excision vs. observation. *Ann Surg Oncol.* 2015;22(5):1479-82. doi: 10.1245/s10434-014-4091-x.
10. Douglas-Jones AG, Denson JL, Cox AC, Harries IB, Stevens G. Radial scar lesions of the breast diagnosed by needle core biopsy: analysis of cases containing occult malignancy. *J Clin Pathol.* 2007;60(3):295-8.
11. Liu RQ, Chen L, Padilla-Thornton A, Pao JS, Warburton R, Dingee C, et al. Upstage rate of radial scar/complex sclerosing lesion identified on core needle biopsy. *Am J Surg.* 2021;221(6):1177-81. doi: 10.1016/j.amjsurg.2021.03.029.
12. Farshid G, Buckley E. Meta-analysis of upgrade rates in 3163 radial scars excised after needle core biopsy diagnosis. *Breast Cancer Res Treat.* 2019;174(1):165-77. doi: 10.1007/s10549-018-5040-3.
13. Rakha E, Beca F, D'Andrea M et al. Outcome of radial scar/complex sclerosing lesion associated with epithelial proliferations with atypia diagnosed on breast core biopsy: results from a multicentric UK-based study. *J Clin Pathol.* 2019;72(12):800-4. doi: 10.1136/jclinpath-2019-205764.

## Risk of malignant disease during follow-up\*

\* i.e. ipsilateral or contralateral disease irrespective of localization of prior lesion

Risk lesion	Upgrade rate to in situ or invasive Ca
LIN/LCIS	7x / 10 yrs (ipsi-/contralateral)
Atypical ductal hyperplasia (ADH)	3-5x / 10 years (ipsi-/contralateral)
Papilloma	
<ul style="list-style-type: none"> <li>no atypia</li> </ul>	4.6% (ipsilateral)
<ul style="list-style-type: none"> <li>atypia</li> </ul>	13% (ipsilateral)

### Allgemeines

1. Stewen K, Theis A, Teifke A, et al.: Benigne und präinvasive Läsion der Brust. *Frauenheilkunde up2date* 2019; 13: 423-439.

### LIN

1. Bodian, C. A., Perzin, K. H. & Lattes, R. Lobular neoplasia. Long term risk of breast cancer and relation to other factors. *Cancer* **78**, 1024–1034 (1996).
2. Page, D. L. *et al.* Atypical lobular hyperplasia as a unilateral predictor of breast cancer risk: a retrospective cohort study. *The Lancet* **361**, 125–129 (2003).
3. Chuba, P. J. *et al.* Bilateral risk for subsequent breast cancer after lobular carcinoma-in-situ: analysis of surveillance, epidemiology, and end results data. *Journal of Clinical Oncology* **23**, 5534–5541 (2005).
4. Ansquer, Y. *et al.* Risk of invasive breast cancer after lobular intra-epithelial neoplasia: review of the literature. *European journal of surgical oncology : the journal of the European Society of Surgical Oncology and the British Association of Surgical Oncology* **36**, 604–609 (2010).
5. McEvoy, M. P. *et al.* Breast Cancer Risk and Follow-up Recommendations for Young Women Diagnosed with Atypical Hyperplasia

and Lobular Carcinoma In Situ (LCIS). *Annals of Surgical Oncology* **22**, 3346–3349 (2015).

6. Nakhliis, F. *et al.* Incidence of Adjacent Synchronous Invasive Carcinoma and/or Ductal Carcinoma In-situ in Patients with Lobular Neoplasia on Core Biopsy: Results from a Prospective Multi-Institutional Registry (TBCRC 020). *Annals of Surgical Oncology* (2015) doi:10.1245/s10434-015-4922-4.
7. King, T. A. *et al.* Lobular Carcinoma in Situ: A 29-Year Longitudinal Experience Evaluating Clinicopathologic Features and Breast Cancer Risk. *Journal of Clinical Oncology* **33**, 3945–3952 (2015).

## ADH


1. Page, D. L., Dupont, W. D., Rogers, L. W. & Rados, M. S. Atypical hyperplastic lesions of the female breast. A long-term follow-up study. *Cancer* **55**, 2698–2708 (1985)
2. Boughey, J. C. *et al.* Evaluation of the Tyrer-Cuzick (International Breast Cancer Intervention Study) model for breast cancer risk prediction in women with atypical hyperplasia. *Journal of Clinical Oncology* **28**, 3591–3596 (2010).
3. Buckley, E., Sullivan, T., Farshid, G., Hiller, J. & Roder, D. Risk profile of breast cancer following atypical hyperplasia detected through organized screening. *Breast (Edinburgh, Scotland)* **24**, 208–212 (2015).
4. Reimers, L. L., Crew, K. D. & Terry, M. B. Atypical hyperplasia of the breast. *The New England journal of medicine* **372**, 1270–1271 (2015).
5. Renshaw, A. A. & Gould, E. W. Long term clinical follow-up of atypical ductal hyperplasia and lobular carcinoma in situ in breast core needle biopsies. *Pathology* **48**, 25–29 (2016).
6. Collins, L. C. *et al.* Breast cancer risk by extent and type of atypical hyperplasia: An update from the Nurses' Health Studies. *Cancer* **122**, 515–520 (2016).
7. Mazzola, E. *et al.* Reassessing risk models for atypical hyperplasia: age may not matter. *Breast Cancer Research and Treatment* **165**, 285–291 (2017).
8. Degnim, A. C. *et al.* Model for Predicting Breast Cancer Risk in Women With Atypical Hyperplasia. *Journal of Clinical Oncology* **36**, 1840–1846 (2018).

## Papillome

1. Brogi, E. & Krystel-Whittemore, M. Papillary neoplasms of the breast including upgrade rates and management of intraductal

- papilloma without atypia diagnosed at core needle biopsy. *Modern Pathol* **34**, 78–93 (2021).
2. Nakhliis, F. *et al.* The Incidence of Adjacent Synchronous Invasive Carcinoma and/or Ductal Carcinoma In Situ in Patients with Intraductal Papilloma without Atypia on Core Biopsy: Results from a Prospective Multi-Institutional Registry (TBCRC 034). *Ann Surg Oncol* **28**, 2573–2578 (2021).
  3. Page, D. L., Salhany, K. E., Jensen, R. A. & Dupont, W. D. Subsequent breast carcinoma risk after biopsy with atypia in a breast papilloma. *Cancer* **78**, 258–266 (1996).
  4. Ciatto, S. *et al.* The Risk of Breast Cancer Subsequent to Histologic Diagnosis of Benign Intraductal Papilloma Follow-Up Study of 339 Cases. *Tumori J* **77**, 41–43 (1991).





© AGO e. V.  
in der DGGG e.V.  
sowie  
in der DKG e.V.

Guidelines Breast  
Version 2024.1E

www.ago-online.de

FORSCHEN  
LEBEN  
HEILEN

## LCIS with elevated risk

---

- **Non-classical LCIS:**
  - **Pleomorphic LCIS:** high-grade cellular atypia, common involvement of ducts with comedo necrosis and microcalcifications
  - **Florid LCIS:** involvement of multiple lobuli with a maximum extension until confluence and involvement of ductuli and neighboring TDLU
- **Microinvasion in classical and non-classical LCIS\*:**
  - classical LCIS: n = 11
  - florid LCIS: n = 4
  - pleomorphic LCIS: n = 1

**Microinvasion in 0.37% of all LCIS (n = 4310) and in 0.43% among all invasive lobular breast cancers (n = 3740).**

\* Ross DS & Hoda SA. Am J Surg Pathol 2011; 35: 750–6.

Statement: Pleomorphic lobular carcinoma in situ (PLCIS)

1. Khoury, T. *et al.* Pleomorphic lobular carcinoma in situ of the breast: clinicopathological review of 47 cases. *Histopathology* **64**, 981–993 (2014).
2. Flanagan, M. R., Rendi, M. H., Calhoun, K. E., Anderson, B. O. & Javid, S. H. Pleomorphic Lobular Carcinoma In Situ: Radiologic-Pathologic Features and Clinical Management. *Annals of Surgical Oncology* **22**, 4263–4269 (2015).
3. Brot, M. D. *et al.* Pleomorphic lobular carcinoma in situ of the breast: a single institution experience with clinical follow-up and centralized pathology review. *Breast Cancer Research and Treatment* **165**, 411–420 (2017).
4. Altundag, K. Uncertainties in the management of pleomorphic lobular carcinoma in situ of the breast still remain. *Journal of B.U.ON. : official journal of the Balkan Union of Oncology* **23**, 273 (2018).
5. Desai, A. A. *et al.* Treatment Outcomes for Pleomorphic Lobular Carcinoma In Situ of the Breast. *Annals of Surgical Oncology* **25**, 3064–3068 (2018).
6. Foschini, M. P. *et al.* Pre-operative management of Pleomorphic and florid lobular carcinoma in situ of the breast: Report of a large multi-institutional series and review of the literature. *Eur J Surg Oncol* **45**, 2279–2286 (2019).
7. Nakhliis, F. *et al.* Evaluating the Rate of Upgrade to Invasive Breast Cancer and/or Ductal Carcinoma In Situ Following a Core Biopsy Diagnosis of Non-classic Lobular Carcinoma In Situ. *Annals of Surgical Oncology* **26**, 55–61 (2019).
8. Kavesh, M., Martinez, M. & Asirvatham, J. R. Pleomorphic lobular carcinoma in situ composed of signet ring cells mimicking

- cribriform ductal carcinoma in situ. *Breast J* **26**, 2050–2051 (2020).
9. Singh, K., Sung, C. J. & Quddus, M. R. Descriptive study comparing outcomes of classic and nonclassic lobular carcinoma in situ (florid and pleomorphic) initially diagnosed on core needle biopsy. *Breast J* **26**, 2350–2356 (2020).
  10. Brogi, E. The morphologic spectrum of lobular carcinoma in situ (LCIS) observations on clinical significance, management implications and diagnostic pitfalls of classic, florid and pleomorphic LCIS. *Virchows Arch* **481**, 823–837 (2022).
  11. Nakhlis, F. *et al.* Presence of Non-classic LCIS Is Not a Contraindication to Breast Conservation in Patients with Concomitant Invasive Breast Cancer or DCIS. *Ann Surg Oncol* **29**, 7696–7702 (2022).

Statement: Florid lobular carcinoma in situ (FLCIS)

1. Calhoun, B. C. & Collins, L. C. Recommendations for excision following core needle biopsy of the breast: a contemporary evaluation of the literature. *Histopathology* **68**, 138–151 (2016).
2. Graziano, L. *et al.* Lobular Carcinoma in Situ with Atypical Mass Presentation: a Case Report. *Revista brasileira de ginecologia e obstetrícia : revista da Federação Brasileira das Sociedades de Ginecologia e Obstetrícia* **38**, 112–116 (2016).
3. Singh, K. *et al.* Evaluating agreement, histological features, and relevance of separating pleomorphic and florid lobular carcinoma in situ subtypes. *Human Pathology* **78**, 163–170 (2018).
4. Shamir, E. R. *et al.* Pleomorphic and Florid Lobular Carcinoma In Situ Variants of the Breast. *Am J Surg Pathology* **43**, 399–408 (2019).
5. Singh, K., Sung, C. J. & Quddus, M. R. Descriptive study comparing outcomes of classic and nonclassic lobular carcinoma in situ (florid and pleomorphic) initially diagnosed on core needle biopsy. *Breast J* **26**, 2350–2356 (2020).
6. Brogi, E. The morphologic spectrum of lobular carcinoma in situ (LCIS) observations on clinical significance, management implications and diagnostic pitfalls of classic, florid and pleomorphic LCIS. *Virchows Arch* **481**, 823–837 (2022).
7. Nakhlis, F. *et al.* Presence of Non-classic LCIS Is Not a Contraindication to Breast Conservation in Patients with Concomitant Invasive Breast Cancer or DCIS. *Ann Surg Oncol* **29**, 7696–7702 (2022).

Statement: Lobular carcinoma in situ with microinvasion

1. Nemoto, T., Castillo, N., Tsukada, Y *et al.* (1998). Lobular carcinoma in situ with microinvasion. *Journal of Surgical Oncology*, 67(1), 41–46.
2. Howat AJ, Armour A, Ellis IO. Microinvasive lobular carcinoma of the breast. *Histopathology*. 2000;37(5):477-478.
3. Ross, D. S., & Hoda, S. A. (2011). Microinvasive (T1mic) lobular carcinoma of the breast: clinicopathologic profile of 16 cases. *The*

American Journal of Surgical Pathology, 35(5), 750–756. <http://doi.org/10.1097/PAS.0b013e318212acd3>

## Strategy after Diagnosis of LIN / LCIS

	Oxford		
	LoE	GR	AGO
<ul style="list-style-type: none"> <li> <b>LIN / LCIS in core- / vacuum-assisted biopsy:</b> <ul style="list-style-type: none"> <li>No further measures if LIN (LCIS, classical variant) with involvement of ≤ 3 TDLU (terminal ductulo-lobular unit) in vacuum biopsy and concordant with imaging.</li> <li>Open excisional biopsy, with pleomorphic LIN, florid LIN (LIN 3), or LIN with comedo type necrosis or if not concordant with imaging findings.</li> </ul> </li> </ul>	2b	C	++
<ul style="list-style-type: none"> <li> <b>LIN / LCIS at margins of resection specimen (BCT):</b> <ul style="list-style-type: none"> <li>No further surgery.</li> </ul> </li> </ul>	2a	C	++

**Exceptions:**

- Pleomorphic, florid, or LIN / LCIS with necrosis
- Imaging abnormality is not removed

### LIN in core- / vacuum-assisted biopsy (LoE 2b)

- Kunjummen, J., Rodriguez, K., Newell, M. S., Hanley, K. & Cohen, M. A. Management of Lobular Neoplasia Found on Core Needle Biopsy Performed for Calcifications Using Precise Radiologic-Pathologic Correlation. *Am J Roentgenol* **216**, 1476–1485 (2021).
- Lewin, A. A. & Mercado, C. L. Atypical Ductal Hyperplasia and Lobular Neoplasia: Update and Easing of Guidelines. *American Journal of Roentgenology* **214**, 265–275 (2020).
- Boland, P. A. *et al.* Lobular intraepithelial neoplasia: Outcomes and optimal management. *Breast J* **26**, 2383–2390 (2020).
- Hoffman, D. I., Zhang, P. J. & Tchou, J. Breast-conserving surgery for pure non-classic lobular carcinoma in situ: A single institution's experience. *Surgical Oncology* **28**, 190–194 (2019).
- Schmidt, H. *et al.* Observation versus excision of lobular neoplasia on core needle biopsy of the breast. *Breast Cancer Research and Treatment* **168**, 649–654 (2018).
- Taylor, L. J. *et al.* Surgical Management of Lobular Carcinoma In Situ: Analysis of the National Cancer Database. *Annals of Surgical Oncology* **25**, 2229–2234 (2018).
- Khoury, M. E. *et al.* Is the outcome at surgery different when flat epithelial atypia and lobular neoplasia are found in association at biopsy? *Br J Radiology* **90**, 20160750 (2017).
- Racz, J. M., Carter, J. M. & Degnim, A. C. Lobular Neoplasia and Atypical Ductal Hyperplasia on Core Biopsy: Current Surgical

Management Recommendations. *Annals of Surgical Oncology* **24**, 2848–2854 (2017).

9. Obeng-Gyasi, S., Ong, C. & Hwang, E. S. Contemporary management of ductal carcinoma in situ and lobular carcinoma in situ. *Chinese clinical oncology* **5**, 32 (2016).
10. Sen, L. Q. C. *et al.* Core Breast Biopsies Showing Lobular Carcinoma In Situ Should Be Excised and Surveillance Is Reasonable for Atypical Lobular Hyperplasia. *American Journal of Roentgenology* **207**, 1132–1145 (2016).
11. Khoury, T. *et al.* Lobular neoplasia detected in MRI-guided core biopsy carries a high risk for upgrade: a study of 63 cases from four different institutions. *Modern Pathology* **29**, 25–33 (2016).
12. Calhoun, B. C. *et al.* Lobular neoplasia diagnosed on breast Core biopsy: frequency of carcinoma on excision and implications for management. *Annals of diagnostic pathology* **25**, 20–25 (2016).
13. Renshaw, A. A. & Gould, E. W. Long term clinical follow-up of atypical ductal hyperplasia and lobular carcinoma in situ in breast core needle biopsies. *Pathology* **48**, 25–29 (2016).
14. Calhoun, B. C. & Collins, L. C. Recommendations for excision following core needle biopsy of the breast: a contemporary evaluation of the literature. *Histopathology* **68**, 138–151 (2016).

LIN accompanying intraductal or invasive carcinoma in patients with BCT (LoE 2a)

1. Ciocca R: Presence of lobular carcinoma in situ does not increase recurrence in patients treated with breast-conserving therapy. *Ann Surg Oncol* 2008; 15:2263-2271

## Strategy after Diagnosis of FEA

	Oxford		
	LoE	GR	AGO
<ul style="list-style-type: none"> <li>▪ <b>FEA in core biopsy / vacuum-assisted biopsy:</b> <ul style="list-style-type: none"> <li>▪ Open excisional biopsy</li> <li>▪ Open excisional biopsy may be omitted under the following circumstances:                             <ul style="list-style-type: none"> <li>a. a small lesion (<math>\leq 2</math> TDLU* in vacuum biopsy) <u>and</u></li> <li>b. Complete or near complete removal of imaging abnormality</li> </ul> </li> </ul> </li> <li>▪ <b>FEA at margins in resection specimen:</b> <ul style="list-style-type: none"> <li>▪ No further surgery, unless calcifications have not been completely removed</li> </ul> </li> </ul>	2b	B	+
	2b	B	+
	3b	C	++

\* TDLU = Terminal ductal-lobular unit

1. Calhoun, B. C. *et al.* Management of flat epithelial atypia on breast core biopsy may be individualized based on correlation with imaging studies. *Modern Pathol* **28**, 670–676 (2015).
2. Acott, A. A. & Mancino, A. T. Flat epithelial atypia on core needle biopsy, must we surgically excise? *Am J Surg* **212**, 1211–1213 (2016).
3. Berry, J. S. *et al.* Analysis of Clinical and Pathologic Factors of Pure, Flat Epithelial Atypia on Core Needle Biopsy to Aid in the Decision of Excision or Observation. *J Cancer* **7**, 1–6 (2016).
4. Samples, L. S. *et al.* Surgical implications and variability in the use of the flat epithelial atypia diagnosis on breast biopsy specimens. *Breast* **34**, 34–43 (2017).
5. Khoury, M. E. *et al.* Is the outcome at surgery different when flat epithelial atypia and lobular neoplasia are found in association at biopsy? *Br J Radiology* **90**, 20160750 (2017).
6. Chan, P. M. Y. *et al.* Majority of flat epithelial atypia diagnosed on biopsy do not require surgical excision. *Breast* **37**, 13–17 (2018).
7. Schiaffino, S. *et al.* Flat epithelial atypia: conservative management of patients without residual microcalcifications post-vacuum-assisted breast biopsy. *Br J Radiology* **91**, 20170484 (2018).
8. McCroskey, Z. *et al.* Flat epithelial atypia in directional vacuum-assisted biopsy of breast microcalcifications: surgical excision may not be necessary. *Modern Pathol* **31**, 1097–1106 (2018).
9. Rageth, C. J. *et al.* Second International Consensus Conference on lesions of uncertain malignant potential in the breast (B3 lesions).

*Breast Cancer Res Tr* **174**, 279–296 (2019).

10. Alencherry, E. *et al.* Clinical, imaging, and intervention factors associated with the upgrade of isolated flat epithelial atypia. *Clin Imag* **54**, 21–24 (2019).
11. Liu, C. *et al.* Pure flat epithelial atypia identified on core needle biopsy does not require excision. *Eur J Surg Oncol* **46**, 235–239 (2020).
12. Srour, M. K. *et al.* Flat epithelial atypia on core needle biopsy does not always mandate excisional biopsy. *Breast J* **26**, 679–684 (2020).
13. Grabenstetter, A., Brennan, S., Salagean, E. D., Morrow, M. & Brogi, E. Flat Epithelial Atypia in Breast Core Needle Biopsies With Radiologic-Pathologic Concordance. *Am J Surg Pathology* **44**, 182–190 (2020).
14. Wahab, R. A., Lee, S.-J., Mulligan, M. E., Zhang, B. & Mahoney, M. C. Upgrade Rate of Pure Flat Epithelial Atypia Diagnosed at Core Needle Biopsy: A Systematic Review and Meta-Analysis. *Radiology Imaging Cancer* **3**, e200116 (2021).
15. Ferre, R. & Kuzmiak, C. M. Flat epithelial atypia: What the radiologist needs to know in 2021. *Clin Imag* **75**, 150–156 (2021).



© AGO e. V.  
in der DGGG e.V.  
sowie  
in der DKG e.V.

Guidelines Breast  
Version 2024.1E

www.ago-online.de

FORSCHEN  
LEBEN  
HEILEN

## Papilloma

- **Includes:** Central and peripheral papilloma > 2 mm, atypical intraductal papilloma (B3)
- To be **distinguished from** peripheral micropapilloma arising in the TDLU, size ≤ 2 mm, may be multiple
- To be distinguished from papilloma with DCIS, from intraductal papillary carcinoma, and from encapsulated papillary carcinoma
- **Precursor lesion:**  
May be associated with in-situ or invasive cancer (up to 6% without atypia if concordant imaging, up to 30% with atypia), increased ipsilateral risk for cancer (up to 4.6% and up to 13% in case of atypical papilloma) .

1. World Health Organization: WHO Classification of Tumours of the Breast. Lokuhetty D, White VA, Watanabe R, Cree IA (Hrsg.) 2019.
2. Tse GM. Papillary lesions of the breast. *Diagnostic Histopathology*. 2018;24(2):64-70. doi:10.1016/j.mpdhp.2017.12.005.
3. Rakha EA, Ellis IO. Diagnostic challenges in papillary lesions of the breast. *Pathology*. 2018;50(1):100-110. doi:10.1016/j.pathol.2017.10.005.
4. Racz JM, Carter JM, Degnim AC. Challenging Atypical Breast Lesions Including Flat Epithelial Atypia, Radial Scar, and Intraductal Papilloma. *Ann Surg Oncol*. 2017;24(10):2842-2847. doi:10.1245/s10434-017-5980-6.
5. Agoumi M, Giambattista J, Hayes MM. Practical Considerations in Breast Papillary Lesions: A Review of the Literature. *Arch Pathol Lab Med*. 2016;140(8):770-790. doi:10.5858/arpa.2015-0525-RA.
6. Saladin C, Haueisen H, Kampmann G, et al. Lesions with unclear malignant potential (B3) after minimally invasive breast biopsy: evaluation of vacuum biopsies performed in Switzerland and recommended further management. *Acta Radiol*. 2016;57(7):815-821. doi:10.1177/0284185115610931.
7. Ni Y-B, Tse GM. Pathological criteria and practical issues in papillary lesions of the breast - a review. *Histopathology*. 2016;68(1):22-32. doi:10.1111/his.12866.
8. Länger F, Hille-Baetz U, Kreipe H-H. Papilläre Läsionen der Mamma. *Der Pathologe*. 2014;35(1):36-44. doi:10.1007/s00292-013-1839-1.



## Strategy after Diagnosis of Papilloma

	Oxford		
	LoE	GR	AGO
<ul style="list-style-type: none"> <li>▪ <b>Papilloma without atypia in core needle or vacuum biopsy:</b> <ul style="list-style-type: none"> <li>→ no further therapy, if biopsy sufficiently representative (100mm<sup>3</sup>) and concordant with imaging</li> </ul> </li> </ul>	2b	C	+
<ul style="list-style-type: none"> <li>▪ <b>Multiple papillomas (&gt;2 mm)</b> <ul style="list-style-type: none"> <li>→ open biopsy</li> </ul> </li> </ul>	3a	C	++
<ul style="list-style-type: none"> <li>▪ <b>Papilloma with atypia in core needle or vacuum biopsies:</b> <ul style="list-style-type: none"> <li>→ open biopsy</li> </ul> </li> </ul>	3a	C	++
<ul style="list-style-type: none"> <li>▪ <b>Papilloma at resection margin:</b> <ul style="list-style-type: none"> <li>→ no published data available</li> </ul> </li> </ul>			

1. Jee, Y. *et al.* Intraductal Papilloma on Breast Biopsy: Upstaging Rate and Implications for Practice Guidelines. *Am Surg* **88**, 1467–1470 (2022).
2. Corbin, H. *et al.* Upgrade rates of intraductal papilloma with and without atypia diagnosed on core needle biopsy and clinicopathologic predictors. *Hum Pathol* **128**, 90–100 (2022).
3. Brogi, E. & Krystel-Whittemore, M. Papillary neoplasms of the breast including upgrade rates and management of intraductal papilloma without atypia diagnosed at core needle biopsy. *Modern Pathol* **34**, 78–93 (2021).
4. Nakhlis, F. *et al.* The Incidence of Adjacent Synchronous Invasive Carcinoma and/or Ductal Carcinoma In Situ in Patients with Intraductal Papilloma without Atypia on Core Biopsy: Results from a Prospective Multi-Institutional Registry (TBCRC 034). *Ann Surg Oncol* **28**, 2573–2578 (2021).
5. Lin, L. H. *et al.* Upgrade rate of intraductal papilloma diagnosed on core needle biopsy in a single institution. *Hum Pathol* **110**, 43–49 (2021).
6. Li, X. *et al.* A retrospective observational study of intraductal breast papilloma and its coexisting lesions: A real-world experience. *Cancer Med-us* **9**, 7751–7762 (2020).
7. Ma, Z. *et al.* Patients with benign papilloma diagnosed on core biopsies and concordant pathology-radiology findings can be followed: experiences from multi-specialty high-risk breast lesion conferences in an academic center. *Breast Cancer Res Tr* **183**, 577–584 (2020).

8. Genco, I. S., Tugertimur, B., Manolas, P. A., Hasanovic, A. & Hajiyeva, S. Upgrade rate of intraductal papilloma without atypia on breast core needle biopsy: A clinical, radiological and pathological correlation study. *Am J Surg* **220**, 677–681 (2020).
9. MacColl, C. *et al.* Benign breast papillary lesions diagnosed on core biopsy: upgrade rate and risk factors associated with malignancy on surgical excision. *Virchows Arch* **475**, 701–707 (2019).
10. Choi, H. Y. *et al.* Benign Breast Papilloma without Atypia: Outcomes of Surgical Excision versus US-guided Directional Vacuum-assisted Removal or US Follow-up. *Radiology* **293**, 72–80 (2019).
11. Qiu, L. *et al.* Diagnosis of Papillary Breast Lesions on Core Needle Biopsy: Upgrade Rates and Interobserver Variability. *Int J Surg Pathol* **27**, 736–743 (2019).
12. Chen, Y. A. *et al.* Excision recommended in high-risk patients: Revisiting the diagnosis of papilloma on core biopsy in the context of patient risk. *Breast J* **25**, 232–236 (2019).
13. Liu, C. *et al.* Risk of malignancy in papillary neoplasms of the breast. *Breast Cancer Res Tr* **178**, 87–94 (2019).
14. Kiran, S. *et al.* Are we overtreating intraductal papillomas? *The Journal of surgical research* **231**, 387–394 (2018).

## Radially Sclerosing Lesion

- **Benign pseudoinfiltrative lesion with central fibroelastic core and radial configuration.**
- **Includes:**
  - radial scar (usually  $\leq 1$  cm)
  - complex sclerosing lesion ( $> 1$  cm)
- **Additional risk factor in patients with benign epithelial hyperplasia (proliferating breast disease)**
- **Risk for upgrade in open biopsy after diagnosis of a radial sclerosing lesion, depending on the size of the needle (CNB) or method (VAB) and additional atypia: 1–18%**

1. Donaldson, A. R., Sieck, L., Booth, C. N. & Calhoun, B. C. Radial scars diagnosed on breast core biopsy: Frequency of atypia and carcinoma on excision and implications for management. *Breast (Edinburgh, Scotland)* **30**, 201–207 (2016).
2. Leong, R. Y., Kohli, M. K., Zeizafoun, N., Liang, A. & Tartter, P. I. Radial Scar at Percutaneous Breast Biopsy That Does Not Require Surgery. *Journal of the American College of Surgeons* **223**, 712–716 (2016).
3. Li, Z., Ranade, A. & Zhao, C. Pathologic findings of follow-up surgical excision for radial scar on breast core needle biopsy. *Human Pathology* **48**, 76–80 (2016).
4. Kalife, E. T., Lourenco, A. P., Baird, G. L. & Wang, Y. Clinical and Radiologic Follow-up Study for Biopsy Diagnosis of Radial Scar/Radial Sclerosing Lesion without Other Atypia. *Breast Journal* **22**, 637–644 (2016).
5. Cohen, M. A. & Newell, M. S. Radial Scars of the Breast Encountered at Core Biopsy: Review of Histologic, Imaging, and Management Considerations. *Am J Roentgenol* **209**, 1168–1177 (2017).
6. Ferreira, A. I. *et al.* Radial scar of the breast: Is it possible to avoid surgery? *European journal of surgical oncology : the journal of the European Society of Surgical Oncology and the British Association of Surgical Oncology* **43**, 1265–1272 (2017).
7. Racz, J. M., Carter, J. M. & Degnim, A. C. Challenging Atypical Breast Lesions Including Flat Epithelial Atypia, Radial Scar, and Intraductal Papilloma. *Ann Surg Oncol* **24**, 2842–2847 (2017).
8. Chou, W. Y. Y., Veis, D. J. & Aft, R. Radial scar on image-guided breast biopsy: is surgical excision necessary? *Breast Cancer Research and Treatment* **170**, 313–320 (2018).

9. Salemis, N. S., Katikaridis, I., Birpanagos, C., Sambaziotis, D. & Sofronas, A. Complex radial sclerosing lesion of the breast-A great cancer mimicker. *Breast Journal* **24**, 408–410 (2018).
10. Rakha, E. *et al.* Outcome of radial scar/complex sclerosing lesion associated with epithelial proliferations with atypia diagnosed on breast core biopsy: results from a multicentric UK-based study. *J Clin Pathol* **72**, 800 (2019).
11. Eghtedari, M. *et al.* Not all patients with a diagnosis of a radial scar require excision. *Breast J* **25**, 792–794 (2019).
12. Farshid, G. & Buckley, E. Meta-analysis of upgrade rates in 3163 radial scars excised after needle core biopsy diagnosis. *Breast Cancer Res Tr* **174**, 165–177 (2019).
13. Gašljević, G., Hertl, K., Gazić, B., Lamovec, J. & Žgajnar, J. Reducing indications for radial scar surgical excision in Slovenian breast cancer screening program. *Ann Diagn Pathol* **45**, 151438 (2020).
14. Woodward, S. G. *et al.* Is radial scar on core needle biopsy a risk factor for malignancy? A single-center retrospective review and implications for management. *Breast J* **26**, 2011–2014 (2020).
15. Liu, R. Q. *et al.* Upstage rate of radial scar/complex sclerosing lesion identified on core needle biopsy. *Am J Surg* **221**, 1177–1181 (2021).
16. Trombadori, C. M. L. *et al.* Radial Scar: a management dilemma. *La Radiologia Medica* **126**, 774–785 (2021).
17. Alsharif, S., Aldis, A., Subahi, A., Khoury, M. E. & Mesurole, B. Breast MRI Does Not Help Differentiating Radial Scar With and Without Associated Atypia or Malignancy. *Can Assoc Radiologists J* **72**, 759–766 (2021).
18. Zanon, A. B. B. *et al.* Underestimation Rate in the Percutaneous Diagnosis of Radial Scar/Complex Sclerosing Lesion of the Breast: Systematic Review. *Revista Brasileira De Ginecologia E Obstetricia Rbgo - Gynecol Obstetrics* **44**, 067–073 (2022).



9. Salemis, N. S., Katikaridis, I., Birpanagos, C., Sambaziotis, D. & Sofronas, A. Complex radial sclerosing lesion of the breast-A great cancer mimicker. *Breast Journal* **24**, 408–410 (2018).
10. Rakha, E. *et al.* Outcome of radial scar/complex sclerosing lesion associated with epithelial proliferations with atypia diagnosed on breast core biopsy: results from a multicentric UK-based study. *J Clin Pathol* **72**, 800 (2019).
11. Eghtedari, M. *et al.* Not all patients with a diagnosis of a radial scar require excision. *Breast J* **25**, 792–794 (2019).
12. Farshid, G. & Buckley, E. Meta-analysis of upgrade rates in 3163 radial scars excised after needle core biopsy diagnosis. *Breast Cancer Res Tr* **174**, 165–177 (2019).
13. Gašljević, G., Hertl, K., Gazić, B., Lamovec, J. & Žgajnar, J. Reducing indications for radial scar surgical excision in Slovenian breast cancer screening program. *Ann Diagn Pathol* **45**, 151438 (2020).
14. Woodward, S. G. *et al.* Is radial scar on core needle biopsy a risk factor for malignancy? A single-center retrospective review and implications for management. *Breast J* **26**, 2011–2014 (2020).
15. Liu, R. Q. *et al.* Upstage rate of radial scar/complex sclerosing lesion identified on core needle biopsy. *Am J Surg* **221**, 1177–1181 (2021).
16. Trombadori, C. M. L. *et al.* Radial Scar: a management dilemma. *La Radiologia Medica* **126**, 774–785 (2021).
17. Alsharif, S., Aldis, A., Subahi, A., Khoury, M. E. & Mesurole, B. Breast MRI Does Not Help Differentiating Radial Scar With and Without Associated Atypia or Malignancy. *Can Assoc Radiologists J* **72**, 759–766 (2021).
18. Zanon, A. B. B. *et al.* Underestimation Rate in the Percutaneous Diagnosis of Radial Scar/Complex Sclerosing Lesion of the Breast: Systematic Review. *Revista Brasileira De Ginecologia E Obstetricia Rbgo - Gynecol Obstetrics* **44**, 067–073 (2022).

## Breast Cancer Early Detection: Follow-up Imaging for Women Age 50–69 Years with B3-Lesions

	Oxford		
	LoE	GR	AGO
<ul style="list-style-type: none"> <li>▪ <b>FEA, non-atypical papilloma, radial sclerosing lesion</b> <ul style="list-style-type: none"> <li>▪ Screening mammography</li> </ul> </li> </ul>	5	C	++
<ul style="list-style-type: none"> <li>▪ <b>LIN / LCIS</b> <ul style="list-style-type: none"> <li>▪ Mammography (12 months)</li> </ul> </li> </ul>	3a	C	++
<ul style="list-style-type: none"> <li>▪ <b>ADH</b> <ul style="list-style-type: none"> <li>▪ Mammography (12 months)</li> <li>▪ Women with LIN and ADH should be informed about their elevated risk of breast cancer</li> </ul> </li> </ul>	3a	C	++

1. Whiffen A: Predictors of Breast Cancer Development in Women with Atypical Ductal Hyperplasia and Atypical Lobular Hyperplasia. Ann Surg Oncol. 2010 Sep 28. [Epub ahead of print]
2. Weir R: Risk factors for breast cancer in women:a systematic review of the literature. Christchurch: New Zealand Health Technology Assessment (NZHTA); 2007.
3. Chuba PJ: Bilateral Risk for Subsequent Breast Cancer After Lobular Carcinoma-In-Situ: Analysis of Surveillance, Epidemiology, and End Results Data. Journal of Clinical Oncology 2005; 23(24):5534-5541
4. Degnim A: Stratification of breast cancer risk in women with atypia: A Mayo Cohort Study. JCO 2007; 25(19):2671-2677.
5. Youk J: Sonographically guided 14-gauge core needle biopsy of breast mass: A review of 2.420 cases with long-term follow-up. AJR 2007; 190:202-207
6. NCCN, National Comprehensive Cancer Network: Breast cancer screening and diagnosis Version 1.2022; June 2, 2022. USA, www.nccn.org
7. O'Connor A: Decision aids for people facing health treatment or screening decisions (Review). The Cochrane Library 2009;(4):1-35

## Medical Prevention for Patients with Increased Risk of DCIS or Invasive Carcinoma

	Oxford		
	LoE	GR	AGO
▪ Tamoxifen 20 mg/d (5 yrs) for women > 35 years	1a	A	+/-
▪ Low-dose Tamoxifen 5 mg/d* (3 years) independent of menopausal status	1b	B	+/-
▪ Aromatase inhibitors (Exemestane, Anastrozole) for postmenopausal women	1a	A	+/-
▪ Raloxifen for postmenopausal women: Risk reduction of invasive BC only	1a	A	+/-**

**Medical prevention should only be offered after individual and comprehensive counseling; overall benefit depends on classification, age, and pre-existing conditions that may influence occurrence of side effects.**

\* 5 mg Tablet not available; alternatively 10 mg p.o. q2d

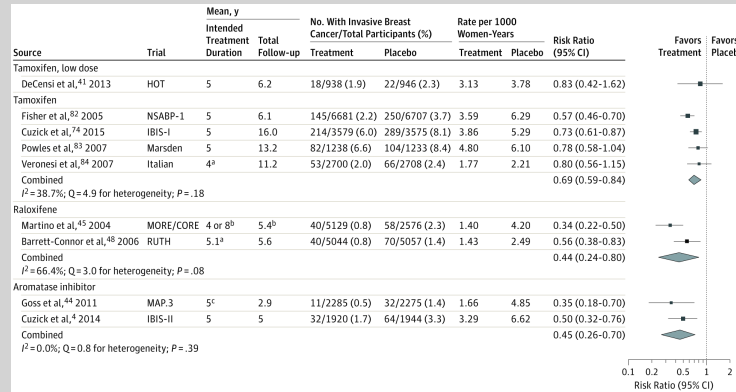
\*\* Risk situation as defined in NSABP P1-trial (1.66% in 5 years)

1. Fischer B: Tamoxifen for the prevention of breast cancer: current status of the national surgical adjuvant breast and bowel project P-1 study. *J Natl Cancer Inst* 2005, 97:1652-1662
2. Cuzick J: Long-term results of tamoxifen prophylaxis for breast cancer - 96 months follow-up of the randomized IBIS-I trial. *J Natl Cancer Inst* 2007; 99:272-282.
3. Goss PE, Ingle JN, Alés-Martínez JE et al.: Exemestane for breast-cancer prevention in postmenopausal women. *N Engl J Med*. 2011 Jun 23;364(25):2381-91.
4. Maunsell E, Goss PE, Chlebowski RT et al.: Quality of life in MAP.3 (Mammary Prevention 3): a randomized, placebo-controlled trial evaluating exemestane for prevention of breast cancer. *J Clin Oncol*. 2014 May 10;32(14):1427-36.
5. Cuzick J, Sestak I, Forbes JF et al.: Anastrozole for prevention of breast cancer in high-risk postmenopausal women (IBIS-II): an international, double-blind, randomised placebo-controlled trial *Lancet* 2014; 383: 1041–48
6. DeCensi A, Puntoni M, Guerrieri-Gonzaga A et al.: Randomized Placebo Controlled Trial of Low-Dose Tamoxifen to Prevent Local and Contralateral Recurrence in Breast Intraepithelial Neoplasia. *J Clin Oncol*. 2019 Jul 1;37(19):1629-1637. doi: 10.1200/JCO.18.01779. Epub 2019 Apr 11.
7. US Preventive Services Task Force, Owens DK, Davidson KW et al.: Medication Use to Reduce Risk of Breast Cancer: US Preventive Services Task Force Recommendation Statement. *JAMA*. 2019 Sep 3;322(9):857-867. doi: 10.1001/jama.2019.11885.
8. Lazzeroni M, Puntoni M, Provinciali N et al.: Estimating the magnitude of clinical benefit of systemic therapy in patients with DCIS or



- pre-invasive disease of the breast. *Breast*. 2019 Nov;48 Suppl 1:S39-S43. doi: 10.1016/S0960-9776(19)31121-X.
9. Flanagan MR, Zabor EC, Stempel M et al.: Chemoprevention Uptake for Breast Cancer Risk Reduction Varies by Risk Factor. *Ann Surg Oncol*. 2019 Jul;26(7):2127-2135. doi: 10.1245/s10434-019-07236-8. Epub 2019 Feb 27.
  10. Marmor S, Jerome-D'Emilia B, Begun JW et al.: Trends in lobular carcinoma in situ management: endocrine therapy use in California and New Jersey. *Cancer Causes Control*. 2019 Feb;30(2):129-136. doi: 10.1007/s10552-019-1126-4. Epub 2019 Jan 17.
  11. Narod, *JAMA Oncol*. 2015 Nov;1(8):1033-4. doi: 10.1001/jamaoncol.2015.2247
  12. Lewin AA, Mercado CL. Atypical Ductal Hyperplasia and Lobular Neoplasia: Update and Easing of Guidelines. *AJR Am J Roentgenol*. 2020; 214:265-275
  13. Visvanathan K, Fabian CJ, Bantug E, et al.: Use of Endocrine Therapy for Breast Cancer Risk Reduction: ASCO Clinical Practice Guideline Update. *J Clin Oncol* 2019; 37: 3152-3165

## Risk Reduction of Invasive Breast Cancer: Meta-analysis of Primary Prevention Trials



Nelson et al. JAMA. 2019;322(9):868-886. doi:10.1001/jama.2019.5780

1. Nelson HD, Rongwei F, et al. Medication Use for the Risk Reduction of Primary Breast Cancer in Women: Updated Evidence Report and Systematic Review for the US Preventive Services Task Force. JAMA . 2019 Sep 3;322(9):868-886