



© AGO e. V.  
in der DGGG e.V.  
sowie  
in der DKG e.V.


Guidelines Breast  
Version 2024.1D

FORSCHEN  
LEHREN  
HEILEN

# Diagnostik und Therapie früher und fortgeschrittener Mammakarzinome

## Pathologie

# Pathologie



- **Versionen 2004–2023:**  
Blohmer / Costa / Fehm / Friedrichs / Harbeck / Huober /  
Kreipe / Lück / Maass / Schneeweiss / Sinn / Thomssen / Schmidt
- **Version 2024:**  
Harbeck / Kreipe / Sinn

Screened data bases: PubMed 2023

## Search Query:

(Breast Diseases/PA[mh] AND ("2011/01/01"[dp] : "2021/12/31"[dp])) AND ("english"[la] OR "german"[la])

## Guidelines screened

1. WHO, Classification of Tumours Editorial Board. Breast Tumours: WHO Classification of Tumours Lyon (France): International Agency for Research on Cancer; 2019. DOI: 10.1111/his.14091
2. National Comprehensive Cancer Network (NCCN). Breast Cancer (Version 2.2022). [http://www.nccn.org/professionals/physician\\_gls/pdf/breast.pdf](http://www.nccn.org/professionals/physician_gls/pdf/breast.pdf). Accessed Jan 01, 2022
3. Burstein, H. J. *et al.* Customizing local and systemic therapies for women with early breast cancer: the St. Gallen International Consensus Guidelines for treatment of early breast cancer 2021. *Ann Oncol* **32**, 1216–1235 (2021).

4. Leitlinienprogramm Onkologie (Deutsche Krebsgesellschaft, Deutsche Krebshilfe, AWMF). Interdisziplinäre S3-Leitlinie für die Diagnostik, Therapie und Nachsorge des Mammakarzinoms. (2021). [https://www.awmf.org/uploads/tx\\_szleitlinien/032-045OLI\\_S3\\_Mammakarzinom\\_2021-07.pdf](https://www.awmf.org/uploads/tx_szleitlinien/032-045OLI_S3_Mammakarzinom_2021-07.pdf) Accessed Jan 01, 2022
5. Wells CA. Pathology\_Update\_Breast\_Screening. 2014:1-48. <http://www.euref.org/downloads?download=24:european-guidelines-for-quality-assurance-in-breast-cancer-screening-and-diagnosis-pdf>
6. The Royal College of Pathologists. Pathology reporting of breast disease in surgical excision specimens incorporating the dataset for histological reporting of breast cancer. June 2016:1-160. <https://www.rcpath.org/resourceLibrary/g148-breastdataset-hires-jun16-pdf.html>
7. Schweizerische Gesellschaft für Pathologie (2017). Leitlinien zur Sicherung und Förderung der Qualitätskontrolle. [https://sgpath.ch/docs/QRL/QRL\\_SGPath\\_Mamma\\_2017.pdf](https://sgpath.ch/docs/QRL/QRL_SGPath_Mamma_2017.pdf)

## Präanalyse: Fixation

	Oxford		
	LoE	GR	AGO
▪ Minimierung der Zeit bis zur Fixation (kalte Ischämiezeit)	5	D	++
▪ Einhaltung einer minimalen Fixationszeit von 6 Stunden zur Gewährleistung einer optimalen Antigenerhaltung	5	D	++
▪ Optimale Fixationszeit bei Stanzbiopsien: 6–72 h	5	D	++
▪ Optimale Fixationszeit bei Resektaten: 12–72 h	5	D	++
▪ Verwendung neutral gepufferter Formalinlösung	5	D	++

### Antigen preservation

1. Apple, S., Pucci, R., Lowe, A. C., et al. (2011). The effect of delay in fixation, different fixatives, and duration of fixation in estrogen and progesterone receptor results in breast carcinoma. *American Journal of Clinical Pathology*, 135(4), 592–598.
2. De Cecco, L., Musella, V., Veneroni, S., et al. (2009). Impact of biospecimens handling on biomarker research in breast cancer. *BMC Cancer*, 9, 409. <http://doi.org/10.1186/1471-2407-9-409>
3. Kalkman, S., Barentsz, M. W., & van Diest, P. J. (2014). The Effects of Under 6 Hours of Formalin Fixation on Hormone Receptor and HER2 Expression in Invasive Breast Cancer: A Systematic Review. *American Journal of Clinical Pathology*, 142(1), 16–22.
4. Lee, A. H. S., Key, H. P., et al. (2014). The effect of delay in fixation on HER2 expression in invasive carcinoma of the breast assessed with immunohistochemistry and in situ hybridisation. *Journal of Clinical Pathology*, 67(7), 573–575
5. Nagahashi, M., Shimada, Y., Ichikawa, H. et al. (2017). Formalin-fixed paraffin-embedded sample conditions for deep next generation sequencing. *The Journal of Surgical Research*, 220, 125–132. <http://doi.org/10.1016/j.jss.2017.06.077>
6. Portier, B. P., Wang, Z., Downs-Kelly, E., et al. (2013). Delay to formalin fixation “cold ischemia time”: effect on ERBB2 detection by in-situ hybridization and immunohistochemistry. *Modern Pathology*, 26(1), 1–9. doi:10.1038/modpathol.2012.123

7. Wolff, A. C., Hammond, M. E. H., Allison, K. H. et al. (2018). Human Epidermal Growth Factor Receptor 2 Testing in Breast Cancer: American Society of Clinical Oncology/College of American Pathologists Clinical Practice Guideline Focused Update. *Archives of Pathology & Laboratory Medicine*, arpa.2018–0902–SA. <http://doi.org/10.5858/arpa.2018-0902-SA>
8. Yildiz-Aktas, I. Z., Dabbs, D. J., & Bhargava, R. (2012). The effect of cold ischemic time on the immunohistochemical evaluation of estrogen receptor, progesterone receptor, and HER2 expression in invasive breast carcinoma. *Modern Pathology*, 25(8), 1098–1105. <http://doi.org/10.1038/modpathol.2012.59>

#### Retraction artifacts

1. Ragage, F., Debled, M., MacGrogan, G., et al. (2010). Is it useful to detect lymphovascular invasion in lymph node-positive patients with primary operable breast cancer? *Cancer*, 116(13), 3093–3101.
2. Lester, S. C., Bose, S., Chen, Y.-Y., et al. (2009). Protocol for the examination of specimens from patients with invasive carcinoma of the breast. *Arch Pathol Lab Med*, 133(10), 1515–1538.

## Indikationen der Mamma-Zytologie\*

- Mamillensekret
- Tumor\*
- Zyste
- Lymphknoten

	Oxford		
	LoE	GR	AGO
Mamillensekret	5	D	+
Tumor*	5	D	-
Zyste	5	D	+/-
Lymphknoten	5	D	+/-

\* Ultraschall gesteuerte Stanzbiopsie empfohlen

1. Day, C, N Moatamed, AM Fimbres, et al: A Retrospective Study of the Diagnostic Accuracy of Fine-Needle Aspiration for Breast Lesions and Implications for Future Use. *Diagnostic Cytopathology* 36, no. 12 (November 30, 2008): 855–60.
2. Pinder, S E, and J S Reis-Filho. Non-Operative Breast Pathology. *Journal of Clinical Pathology* 60, no. 12 (December 20, 2006): 1297–99. doi:10.1136/jcp.2006.040519.
3. Tse, G M K, T K F Ma, P C W Lui, et al. Fine Needle Aspiration Cytology of Papillary Lesions of the Breast: How Accurate Is the Diagnosis?. *Journal of Clinical Pathology* 61, no. 8 (August 2008): 945–49. doi:10.1136/jcp.2008.057489.
4. Ibrahim AE, Bateman AC, Theaker JM, et al. The role and histological classification of needle core biopsy in comparison with fine needle aspiration cytology in the preoperative assessment of impalpable breast lesions. *J Clin Pathol* 2001;54:121–5.
5. He, X., Wang, Y., Nam, G., Lourenco, A. P. et al. (2018). A 10 year retrospective review of fine needle aspiration cytology of cystic lesions of the breast with emphasis on papillary cystic lesions. *Diagnostic Cytopathology*. <http://doi.org/10.1002/dc.24123>
6. Bruzzone, M., Saro, F., Bruno, S. et al. (2018). Synergy of cytological methods in the pathological staging of breast cancer: Axillary fine-needle aspiration and intraoperative scrape cytology of the sentinel lymph node. *Diagnostic Cytopathology*, 46(11), 919–926. <http://doi.org/10.1002/dc.23995>
7. Tiwari, P., Ghosh, S., & Agrawal, V. K. (2018). Evaluation of breast lesions by digital mammography and ultrasound along with fine-needle aspiration cytology correlation. *Journal of Cancer Research and Therapeutics*, 14(5), 1071–1074.

<http://doi.org/10.4103/0973-1482.191053>

## Aufarbeitung: Stanzbiopsien (Ultraschall gesteuert / stereotaktisch)

	Oxford		
	LoE	GR	AGO
▪ <b>Aufarbeitung in Schnittstufen (14G: 1 – 3 Stufen / 11G, 8G: 6 – 8 Stufen)</b>	5	D	++
▪ <b>Radiologisch-pathologische Korrelation (Mikrokalk / Dichte), Anwendung der B-Klassifikation</b>	1b	B	++
▪ <b>Schnellschnittdiagnostik an Stanzbiopsien</b>	5	D	--
▪ <b>Evaluation des ER/PR und HER2-Status</b>	3b	C	++
▪ <b>Umlaufzeit &lt; 24 h (Dignität)</b>	5	D	+

### Statement: Routine workup in step sections

1. Hahn, M., Krainick-Strobel, U., Toellner, T. et al. (2012). Interdisciplinary consensus recommendations for the use of vacuum-assisted breast biopsy under sonographic guidance: first update 2012. *Ultraschall Med*, 33(4), 366–371. <http://doi.org/10.1055/s-0032-1312831>
2. Sinn, Gerber, Brucker et al. (2017): DCIS und Risikoläsionen. In: AWMF: S3-Leitlinie Früherkennung, Diagnostik, Therapie und Nachsorge des Mammakarzinoms, S. 79 - 89.

### Statement: Correlation with imaging

1. Heywang-Köbrunner SH, Sinnatamby R, Lebeau A, et al; Consensus Group. Interdisciplinary consensus on the uses and technique of MR-guided vacuum-assisted breast biopsy (VAB): results of a European consensus meeting. *Eur J Radiol*. 2009 Nov;72(2):289-94
2. Sinn, Gerber, Brucker et al. (2017): DCIS und Risikoläsionen. In: AWMF: S3-Leitlinie Früherkennung, Diagnostik, Therapie und Nachsorge des Mammakarzinoms, S. 79 - 89.



Statement: Frozen section diagnosis on core biopsies

1. Lebeau, Gerber, Brucker et al. (2017): Pathomorphologische Untersuchung. In: AWMF: S3-Leitlinie Früherkennung, Diagnostik, Therapie und Nachsorge des Mammakarzinoms, S. 100 - 139.
2. Dämmrich, M., Thomssen, C., Hillemanns, P. et al. (2012). Intraoperative pathologische Sofortuntersuchung in der Mammachirurgie. *Der Pathologe*, 33(5), 424–429. <http://doi.org/10.1007/s00292-012-1596-6>

Statement: Routine evaluation of ER/PgR and HER-2 status

1. Dekker, T. J. A., Smit, V. T. H. B. M., Hooijer, G. K. J. et al. (2013). Reliability of core needle biopsy for determining ER and HER2 status in breast cancer. *Annals of Oncology*, 24(4), 931–937. <http://doi.org/10.1093/annonc/mds599>
2. Meattini, I., Bicchierai, G., Saieva, C. et al. (2017). Impact of molecular subtypes classification concordance between preoperative core needle biopsy and surgical specimen on early breast cancer management: Single-institution experience and review of published literature. *European Journal of Surgical Oncology : the Journal of the European Society of Surgical Oncology and the British Association of Surgical Oncology*, 43(4), 642–648. <http://doi.org/10.1016/j.ejso.2016.10.025>

Statement: Turn-around time < 24h

1. Amendoeira I, Apostolikas N, Bellocq et al. Quality assurance guidelines for pathology: Open biopsy and resection specimens. In: Perry N, Broders M, de Wolf C, Törnberg S, Holland R, von Karsa L, Puthaar E (eds) European guidelines for quality assurance in breast cancer

## Aufarbeitung: Brusterhaltende Therapie

	Oxford		
	LoE	GR	AGO
▪ Die Lamellierung erfolgt senkrecht zur Längsachse (bzw. bei kugeligen Exzidaten senkrecht zur Mamillen-Peripherie-Achse)	5	D	++
▪ Systematisches Sampling, mindestens ein Gewebeblock pro cm Resektat	5	D	++
▪ Tuschemarkierung der Resektionsränder	5	D	++
▪ Makroskopische Dokumentation der Gewebescheiben durch Präparateradiographie, Photodokumentation oder Diagramm	5	D	+

### Guidelines

1. The Royal College of Pathologists. Pathology reporting of breast disease in surgical excision specimens incorporating the dataset for histological reporting of breast cancer. June 2016:1-160. <https://www.rcpath.org/profession/publications/cancer-datasets.html>.
2. Schnitt SJ, Moran MS, Houssami N, Morrow M. The Society of Surgical Oncology-American Society for Radiation Oncology Consensus Guideline on Margins for Breast-Conserving Surgery With Whole-Breast Irradiation in Stages I and II Invasive Breast Cancer: Perspectives for Pathologists. *Arch Pathol Lab Med*. August 2014. doi:10.5858/arpa.2014-0384-ED.
3. Schweizerische Gesellschaft für Pathologie (2002). Leitlinien zur Sicherung und Förderung der Qualitätskontrolle. [https://sgpath.ch/docs/QRL/QRL\\_SGPath\\_Mamma\\_2017.pdf](https://sgpath.ch/docs/QRL/QRL_SGPath_Mamma_2017.pdf)
4. Lester SC, Bose S, Chen Y-Y, et al. Protocol for the examination of specimens from patients with invasive carcinoma of the breast. *Arch Pathol Lab Med*. 2009;133(10):1515-1538. doi:10.1043/1543-2165-133.10.1515.
5. Lester SC, Bose S, Chen Y-Y, et al. Protocol for the examination of specimens from patients with ductal carcinoma in situ of the breast. *Arch Pathol Lab Med*. 2009;133(1):15-25. doi:10.1043/1543-2165-133.1.15.
6. Fitzgibbons P, Connolly J, Page D. Updated protocol for the examination of specimens from patients with carcinomas of the breast. Cancer Committee. *Arch Pathol Lab Med*. 2000;124(7):1026-1033.

### Systematic Sampling

1. Ang SC, Tapia G, Davidson EJ, et al. Positive anterior margins in breast conserving surgery: Does it matter? A systematic review of the literature. *Breast*. 2016;27:105-108. doi:10.1016/j.breast.2015.12.013.
2. Molina MA, Snell S, Franceschi D, et al. Breast specimen orientation. *Ann Surg Oncol*. 2009;16(2):285-288. doi:10.1245/s10434-008-0245-z.
3. Sinn HP, Anton HW, Magener A, Fournier von D, Bastert G, Otto HF. Extensive and predominant in situ component in breast carcinoma: their influence on treatment results after breast-conserving therapy. *Eur J Cancer*. 1998;34(5):646-653. doi:10.1016/s0959-8049(97)10106-x.
4. Decker T, Ruhnke M, Schneider W. Standardisierte pathologische Untersuchung von Mamma-Exzisionspräparaten. Relevanz innerhalb eines interdisziplinären Praxisprotokolls für das Qualitätsmanagement der brusterhaltenden Therapie. *Der Pathologe*. 1997;18(1):53-59. doi:10.1007/s002920050196.

## Aufarbeitung: Mastektomie

	Oxford		
	LoE	GR	AGO
<ul style="list-style-type: none"> <li>▪ <b>Sampling der Resektionsränder</b> <ul style="list-style-type: none"> <li>▪ Hautränder tumornah</li> <li>▪ dorsaler Rand</li> <li>▪ weitere Ränder, wenn knapp (&lt; 1 cm)</li> </ul> </li> </ul>	5	D	++
<ul style="list-style-type: none"> <li>▪ <b>Beachtung der Weichgewebsränder bei hautsparender Mastektomie</b></li> </ul>	5	D	++
<ul style="list-style-type: none"> <li>▪ <b>Sampling von nicht involvierten Quadranten, Haut über Tumor, Mamille und retroareoläre Region</b></li> </ul>	5	D	++
<ul style="list-style-type: none"> <li>▪ <b>Systematische Probenentnahme bei prophylaktischer Mastektomie (BRCA-1/2 pos. Patienten)</b></li> </ul>	5	D	++

### Guidelines

1. The Royal College of Pathologists. Pathology reporting of breast disease in surgical excision specimens incorporating the dataset for histological reporting of breast cancer. June 2016:1-160. <https://www.rcpath.org/profession/publications/cancer-datasets.html>.
2. Schnitt SJ, Moran MS, Houssami N, Morrow M. The Society of Surgical Oncology-American Society for Radiation Oncology Consensus Guideline on Margins for Breast-Conserving Surgery With Whole-Breast Irradiation in Stages I and II Invasive Breast Cancer: Perspectives for Pathologists. *Arch Pathol Lab Med*. August 2014. doi:10.5858/arpa.2014-0384-ED.
3. Schweizerische Gesellschaft für Pathologie (2002). Leitlinien zur Sicherung und Förderung der Qualitätskontrolle. [https://sgpath.ch/docs/QRL/QRL\\_SGPath\\_Mamma\\_2017.pdf](https://sgpath.ch/docs/QRL/QRL_SGPath_Mamma_2017.pdf)
4. Lester SC, Bose S, Chen Y-Y, et al. Protocol for the examination of specimens from patients with invasive carcinoma of the breast. *Arch Pathol Lab Med*. 2009;133(10):1515-1538. doi:10.1043/1543-2165-133.10.1515.
5. Lester SC, Bose S, Chen Y-Y, et al. Protocol for the examination of specimens from patients with ductal carcinoma in situ of the breast. *Arch Pathol Lab Med*. 2009;133(1):15-25. doi:10.1043/1543-2165-133.1.15.
6. Fitzgibbons P, Connolly J, Page D. Updated protocol for the examination of specimens from patients with carcinomas of the breast. Cancer Committee. *Arch Pathol Lab Med*. 2000;124(7):1026-1033.

### Skin sparing and nipple sparing mastectomy

1. Papassotiropoulos B, Güth U, Chiesa F, et al. Prospective Evaluation of Residual Breast Tissue After Skin- or Nipple-Sparing Mastectomy: Results of the SKINI-Trial. *Ann Surg Oncol*. 2019;26(5):1254-1262. doi:10.1245/s10434-019-07259-1.
2. Mota BS, Riera R, Ricci MD, et al. Nipple- and areola-sparing mastectomy for the treatment of breast cancer. *Cochrane Database Syst Rev*. 2016;11:CD008932. doi:10.1002/14651858.CD008932.pub3.
3. Zhang H, Li Y, Moran MS, Haffty BG, Yang Q. Predictive factors of nipple involvement in breast cancer: a systematic review and meta-analysis. *Breast Cancer Res Treat*. 2015;151(2):239-249. doi:10.1007/s10549-015-3385-4.
4. Wang J, Xiao X, Wang J, et al. Predictors of nipple-areolar complex involvement by breast carcinoma: histopathologic analysis of 787 consecutive therapeutic mastectomy specimens. *Ann Surg Oncol*. 2012;19(4):1174-1180. doi:10.1245/s10434-011-2107-3.
5. Petit JY, Veronesi U, Orecchia R, et al. Risk factors associated with recurrence after nipple-sparing mastectomy for invasive and intraepithelial neoplasia. *Ann Oncol*. January 2012. doi:10.1093/annonc/mdr566.
6. Weidong Li, Shuling Wang, Xiaojing Guo, et al. Nipple involvement in breast cancer: retrospective analysis of 2323 consecutive mastectomy specimens. *International Journal of Surgical Pathology*. 2011;19(3):328-334. doi:10.1177/1066896911399279.
7. Brachtel EF, Rusby JE, Michaelson JS, et al. Occult nipple involvement in breast cancer: clinicopathologic findings in 316 consecutive mastectomy specimens. *J Clin Oncol*. 2009;27(30):4948-4954. doi:10.1200/JCO.2008.20.8785.
8. Güth U, Wight E, Schötzau A, et al. Correlation and significance of histopathological and clinical features in breast cancer with skin involvement (T4b). *Hum Pathol*. 2006;37(3):264-271.
9. Torresan RZ, Santos dos CC, Okamura H, Alvarenga M. Evaluation of residual glandular tissue after skin-sparing mastectomies. *Ann Surg Oncol*. 2005;12(12):1037-1044. doi:10.1245/ASO.2005.11.027.
10. Torresan RZ, Cabello dos Santos C, Brenelli H, Okamura H, Alvarenga M. Residual glandular tissue after skin-sparing mastectomies. *Breast J*. 2005;11(5):374-375. doi:10.1111/j.1075-122X.2005.00029.x.
11. Sikand K, Lee AHS, Pinder SE, Elston CW, Ellis IO. Sections of the nipple and quadrants in mastectomy specimens for carcinoma are of limited value. *SciMed Central*. 2005;58(5):543-545. doi:10.1136/jcp.2004.022665.
12. Love SM, Barsky SH. Anatomy of the nipple and breast ducts revisited. *Cancer*. 2004;101(9):1947-1957. doi:10.1002/cncr.20559.

13. Ho CM, Mak CKL, Lau Y, Cheung WY, Chan MCM, Hung WK. Skin involvement in invasive breast carcinoma: safety of skin-sparing mastectomy. *Ann Surg Oncol*. 2003;10(2):102-107. doi:10.1245/aso.2003.05.001.
14. Simmons RM, Brennan M, Christos P, King V, Osborne M. Analysis of nipple/areolar involvement with mastectomy: can the areola be preserved? *Ann Surg Oncol*. 2002;9(2):165-168.
15. Santini D, Taffurelli M, Gelli MC, et al. Neoplastic involvement of nipple-areolar complex in invasive breast cancer. *Am J Surg*. 1989;158(5):399-403.
16. Lüttges J, Kalbfleisch H, Prinz P. Nipple involvement and multicentricity in breast cancer. A study on whole organ sections. *J Cancer Res Clin Oncol*. 1987;113(5):481-487.
17. Morimoto T, Komaki K, Inui K, et al. Involvement of nipple and areola in early breast cancer. *Cancer*. 1985;55(10):2459-2463.

## Aufarbeitung: Sentinel-Lymphknoten

	Oxford		
	LoE	GR	AGO
▪ <b>Vollständige Aufarbeitung am Paraffinschnitt mit Schnittstufen von <math>\leq 500 \mu\text{m}</math></b>	5	D	++
▪ <b>Zytokeratin-Immunhistologie</b>			
▪ zum Nachweis von Mikrometastasen, wenn suspekt	2b	B	+
▪ zum Nachweis von Mikrometastasen nach NACT	2b	B	+
▪ routinemäßig	5	D	+/-
▪ <b>Schnellschnittuntersuchung (anschließender Paraffinschnitt erschwert)</b>			
▪ bei klinischer Konsequenz	5	D	+
▪ bei nicht zu erwartender Konsequenz	5	D	-
▪ <b>Abtupfzytologie anstatt oder zusätzlich zur Schnellschnittuntersuchung</b>	3b	C	+/-
▪ <b>RT-PCR zum Nachweis von Metastasen</b>	4	D	-
▪ OSNA	3b	B	-

### Statement: Evaluation of sentinel node biopsy

1. Maguire, A., & Brogi, E. (2016). Sentinel lymph nodes for breast carcinoma: an update on current practice. *Histopathology*, 68(1), 152–167. <http://doi.org/10.1111/his.12853>
2. Liu L-C, Lang JE, Lu Y, et al. Intraoperative frozen section analysis of sentinel lymph nodes in breast cancer patients: a meta-analysis and single-institution experience. *Cancer*. 2011;117(2):250-258. doi:10.1002/cncr.25606.

### Statement: Full workup using step sections of $\geq 500 \mu\text{m}$ on paraffin embedded tissue

1. Maguire, A., & Brogi, E. (2016). Sentinel lymph nodes for breast carcinoma: an update on current practice. *Histopathology*, 68(1), 152–167. <http://doi.org/10.1111/his.12853>

### Statement: Frozen section

1. Langer, I., Guller, U., Berclaz, G. et al. (2009). Accuracy of frozen section of sentinel lymph nodes: a prospective analysis of 659 breast cancer patients of the Swiss multicenter study. *Breast Cancer Research and Treatment*, 113(1), 129–136.

<http://doi.org/10.1007/s10549-008-9911-x>

Statement: Imprint cytology instead or in addition of frozen section

1. Layfield et al. Intraoperative assessment of sentinel lymph nodes in breast cancer. *The British journal of surgery* (2011) vol. 98 (1) pp. 4-17
2. Upender, S., Mohan, H., Handa, U. et al. (2009). Intraoperative evaluation of sentinel lymph nodes in breast carcinoma by imprint cytology, frozen section and rapid immunohistochemistry. *Diagnostic Cytopathology*, 37(12), 871–875.  
<http://doi.org/10.1002/dc.21120>

Statement: RT-PCR for epithelial genes

1. Layfield, D. M., Agrawal, A., Roche, H. et al. (2011). Intraoperative assessment of sentinel lymph nodes in breast cancer. *The British Journal of Surgery*, 98(1), 4–17. <http://doi.org/10.1002/bjs.7229>
2. Visser, M., Jiwa, M., Horstman, A. et al. (2008). Intra-operative rapid diagnostic method based on CK19 mRNA expression for the detection of lymph node metastases in breast cancer. *International Journal of Cancer Journal International Du Cancer*, 122(11), 2562–2567. <http://doi.org/10.1002/ijc.23451>



## Aufarbeitung: Intraoperative pathologische Sofortuntersuchung einschließlich Schnellschnitt

	Oxford		
	LoE	GR	AGO
<ul style="list-style-type: none"> <li>▪ <b>Sentinelbiopsie beim invasiven Karzinom</b> (anschließender Paraffinschnitt erschwert) <ul style="list-style-type: none"> <li>▪ bei klinischer Konsequenz</li> <li>▪ bei nicht zu erwartender Konsequenz</li> </ul> </li> </ul>	5	D	+
<ul style="list-style-type: none"> <li>▪ <b>Beurteilung der Resektionsränder</b> <ul style="list-style-type: none"> <li>▪ wenn makroskopisch &lt; 1 cm</li> <li>▪ wenn makroskopisch &gt; 1 cm</li> </ul> </li> </ul>	5	D	+
<ul style="list-style-type: none"> <li>▪ <b>Läsion mit einer Größe von ≥ 1 cm, keine Corebiopsie erfolgt</b></li> </ul>	5	D	+
<ul style="list-style-type: none"> <li>▪ <b>Nicht tastbare Läsion oder Läsion &lt; 1 cm</b></li> </ul>	5	D	--
<ul style="list-style-type: none"> <li>▪ <b>Asservierung von unfixiertem Nativgewebe</b></li> </ul>	5	D	+

### Statement: Sentinel node biopsy for invasive cancer

1. Kühn T, Bembenek A, Decker T et al. A concept for the clinical implementation of sentinel lymph node biopsy in patients with breast carcinoma with special regard to quality assurance. Cancer 2005; 103: 451-461.
2. Grabau D, Rank F, Friis E. Intraoperative frozen section examination of axillary sentinel lymph nodes in breast cancer. APMIS 2005; 113: 7-12.
3. Van Diest PJ, Torrenge H, Borgstein PJ et al. Reliability of intraoperative frozen section and imprint cytological investigation of sentinel lymph nodes in breast cancer. Histopathology 1999; 35: 14-18.

### Statement: Closest margin of resection

1. Reiner-Concin A, Lax S. Mammakarzinom. In: Manual der gynäkologischen Onkologie (Reinthal R, Helfer L, Hrsg.). <http://www.ago-manual.at/inhalt/i-mammakarzinom/15-pathologie/>
2. Kraus-Tiefenbacher U, Scheda A, Steil V, et al. Intraoperative radiotherapy (IORT) for breast cancer using the Intrabeam system. Tumori. 2005;91:339-45

Statement: Lesions  $\geq$  1 cm, without core biopsy

1. Reiner-Concin A, Lax S. Mammakarzinom. In: Manual der gynäkologischen Onkologie (Reinthal R, Helfer L, Hrsg.). <http://www.ago-manual.at/inhalt/i-mammakarzinom/15-pathologie/>
2. Fitzgibbons PL, Connolly JL, Page DL. Updated protocol for the examination of specimens from patients with carcinomas of the breast. Arch Pathol Lab Med 2000; 124:1026- 1033. (ACR)
3. Amendoeira I, Apostolikas N, Bellocq et al. Quality assurance guidelines for pathology: Open biopsy and resection specimens. In: Perry N, Broders M, de Wolf C, et al (eds) European guidelines for quality assurance in breast cancer screening and diagnosis; Office for Official Publications of the European Communities, Luxembourg, 2006, pp 256-311

Statement: Non-palpable lesions or lesions  $<$  1 cm

1. Morrow M, Strom E, Bassett L et al. Standard for the management of ductal carcinoma in situ of the breast (DCIS). CA Cancer J Clin 2002; 52: 256-276.

## Befundung: Histologischer Tumortyp

Oxford		
LoE	GR	AGO
3b	C	++

- **Histologischer Tumortyp entsprechend WHO-Klassifikation (5. Aufl. 2019)**
  - **Partielle spezielle Differenzierung:**  
> 50% NST-Komponente  
und < 50% spezieller Tumortyp (Minorkomponente)
  - **Gemischte Differenzierung:**  
> 50% spezieller Tumortyp  
und < 50% NST-Komponente  
Beispiel: Muzinöses MaCa, Mischtyp
  - **Reine Typen:**  
> 90% des Tumors vom speziellen Typ  
Beispiel: tubuläres oder kribriiformes Ca.


### WHO-Classification

1. Hoon TP, Ellis I, Allison K, et al. The 2019 WHO classification of tumours of the breast. *Histopathology*. February 2020. doi:10.1111/his.14091.
2. WHO. Breast Tumours: WHO Classification of Tumours. 5 ed. Lyon (France): International Agency for Research on Cancer; 2019.
3. Tan, P. H., & Ellis, I. O. (2013). Myoepithelial and epithelial-myoepithelial, mesenchymal and fibroepithelial breast lesions: updates from the WHO Classification of Tumours of the Breast 2012. *Journal of Clinical Pathology*, 66(6), 465–470. doi:10.1136/jclinpath-2012-201078
4. Viale, G. (2012). The current state of breast cancer classification. *Annals of Oncology : Official Journal of the European Society for Medical Oncology / ESMO*, 23 Suppl 10(suppl 10), x207–x210. doi:10.1093/annonc/mds326


Reference	Patients	Results
Villegas, S. L. <i>Eur J Cancer</i> <b>148</b> , 159–170 (2021) DOI: 10.1016/j.ejca.2021.02.020	Neoadjuvant clinical trial cohorts (n = 2765) comparing neg. ER/PR (<1%) vs. ER/PR low pos. (ER and/or PR <9%) vs. strong-pos. (ER or PR ≥ 10%) HR expression.	Low HR-positive, HER2-negative tumours had a similar clinical behavior compared to TNBC, showing high pCR rates and poor survival and also a basal-like gene expression signature. Patients with low HR-positive tumours should be regarded as candidates for therapy strategies targeting TNBC.
Dieci, M. V. et al. <i>Npj Breast Cancer</i> <b>7</b> , 101 (2021) DOI: 10.1038/s41523-021-00308-7	406 patients with ER < 10% HER2-negative BC. Pat. Were categorized in ER-negative (ER < 1%; N = 364) and ER-low positive (1–9%, N = 42).	No difference was observed in overall survival (OS) according to ER expression levels (5-years OAS 82.3% vs. 76.7% for ER-negative and ER-low positive BC, respectively, p = 0.8). Our results suggest the use of a 10% cut-off, rather than <1%, to define triple-negative BC (TNBC).
Reddy, S. M. et al. <i>British Journal of Cancer</i> <b>118</b> , 17–23 (2018) DOI: 10.1038/bjc.2017.379	Stage I-III TNBC pat. (n=873) who were disease free at 5 years from diagnosis. Recurrence-free interval (RFI), r.f. survival (RFS), and distant r.f. survival (DRFS) rates were calculated.	After a disease-free interval of 5 years, patients with low hormone receptor-pos. cancers had a higher risk of late events as measured by RFS, and similar risk by RFI or DRFS, compared to TNBC survivors.

### Chemotherapy response and survival in low-ER BC vs. TNBC

1. Villegas, S. L. *et al.* Therapy response and prognosis of patients with early breast cancer with low positivity for hormone receptors – An analysis of 2765 patients from neoadjuvant clinical trials. *Eur J Cancer* **148**, 159–170 (2021).
2. Dieci, M. V. *et al.* Impact of estrogen receptor levels on outcome in non-metastatic triple negative breast cancer patients treated with neoadjuvant/adjuvant chemotherapy. *Npj Breast Cancer* **7**, 101 (2021).
3. Reddy, S. M. *et al.* Long-term survival outcomes of triple-receptor negative breast cancer survivors who are disease free at 5 years and relationship with low hormone receptor positivity. *British Journal of Cancer* **118**, 17–23 (2018).



ARBEITSGEMEINSCHAFT  
GYNAKOLOGISCHE  
ONKOLOGIE e.V.



12-07-103

© AGO e. V.  
in der DGGG e.V.  
sowie  
in der DKG e.V.

Guidelines Breast  
Version 2024.1D

www.ago-online.de

FORSCHEN  
LEBEN  
HEILEN

## Rare histological TNBC subtypes show divergent tumor differentiation patterns and clinical behavior

**Apocrine TNBC**

- Luminal phenotype (no basal markers)
- High expression of the androgen receptor
- Low tumor proliferation
- Poor response to chemotherapy
- Better prognosis than ductal TNBC

**Metaplastic TNBC**

- See chapter 15 Special Situations

**Rare and salivary-type TNBC**

- Tumors with divergent clinical behavior and specific genetic alterations
- Mostly low tumor proliferation
- Poor response to conventional chemotherapy
- Experimental treatment according to the molecular pathology (e.g. NTREK for secretory ca.)

### Rare histological TNBC subtypes

1. Cserni, G. *et al.* Triple-Negative Breast Cancer Histological Subtypes with a Favourable Prognosis. *Cancers* 13, 5694 (2021).
2. Cima, L. *et al.* Triple-negative breast carcinomas of low malignant potential: review on diagnostic criteria and differential diagnoses. *Virchows Arch* 1–18 (2021) doi:10.1007/s00428-021-03174-7.
3. Schnitt, S. J., Fend, F. & Decker, T. Breast carcinomas of low malignant potential. *Virchows Arch* 1–15 (2021) doi:10.1007/s00428-021-03163-w.
4. Mills, M. N. *et al.* Histologic heterogeneity of triple negative breast cancer: A National Cancer Centre Database analysis. *European journal of cancer (Oxford, England : 1990)* 98, 48–58 (2018).
5. Kandil, D. & Khan, A. Triple negative breast carcinoma: the good, the bad and the ugly. *Diagnostic Histopathology* 18, 210–216 (2012).
6. Montagna, E. *et al.* Heterogeneity of triple-negative breast cancer: histologic subtyping to inform the outcome. *Clinical breast cancer* 13, 31–39 (2013).

Reference	Patients	Results
Saridakis, A. <i>et al.</i> <i>Ann Surg Oncol</i> <b>28</b> , 5610–5616 (2021). DOI: 10.1245/s10434-021-10518-9	Women with invasive apocrine cancer were retrospectively identified from the Surveillance, Epidemiology, and End Results (SEER) database. N= 533 triple-negative apocrine cancers were identified.	Half of apocrine tumors are triple negative, but these have more favorable features and much better survival than non-apocrine triple-negative cancers. Compared with non-apocrine triple-negative, apocrine triple-negative patients were much older, with smaller, lower-grade tumors and much better survival (86% vs. 74%).
Montagna, E. <i>et al.</i> <i>Breast</i> <b>53</b> , 138–142 (2020). DOI: 10.1038/s41523-021-00308-7	406 patients with ER < 10% HER2-negative BC. Pat. Were categorized in ER-negative (ER < 1%; N = 364) and ER-low positive (1–9%, N = 42).	The outcome of selected apocrine triple negative breast cancer patients who did not received adjuvant chemotherapy is excellent and supports a treatment de-escalation.
Mills, A. M., <i>et al.</i> <i>Am J Surg Pathol</i> <b>40</b> , 1109–1116 (2016). DOI: 10.1097/pas.0000000000000671	All pure apocrine carcinomas diagnosed during a 10-year period were reviewed, and clinicopathologic characteristics were compared with a control group of 26 non-apocrine TNBC cases. Twenty apocrine carcinomas were identified (~0.8% of all breast cancers).	Apocrine TNBC had a favorable clinical prognosis, with 80% of patients showing no evidence of disease-related morbidity or mortality (mean follow-up: 45.2 mo). Pure apocrine carcinomas represent a clinicopathologically distinct subgroup of triple-negative breast cancer characterized by AR positivity.



© AGO e. V.  
in der DGGG e.V.  
sowie  
in der DKG e.V.

Guidelines Breast  
Version 2024.1D


www.ago-online.de

FORSCHEN  
LEBEN  
HEILEN

## Apocrine TNBC: More favorable survival and poor response to adjuvant chemotherapy

### Apocrine TNBC

1. Saridakis, A. *et al.* Apocrine Breast Cancer: Unique Features of a Predominantly Triple-Negative Breast Cancer. *Ann Surg Oncol* **28**, 5610–5616 (2021).
2. Montagna, E. *et al.* Prognosis of selected triple negative apocrine breast cancer patients who did not receive adjuvant chemotherapy. *Breast Official J European Soc Mastology* **53**, 138–142 (2020).
3. Mills, A. M., Gottlieb, C. E., Wendroth, S. M., Brenin, C. M. & Atkins, K. A. Pure Apocrine Carcinomas Represent a Clinicopathologically Distinct Androgen Receptor-Positive Subset of Triple-Negative Breast Cancers. *The American journal of surgical pathology* **40**, 1109–1116 (2016).
4. Vranic, S. *et al.* Apocrine carcinoma of the breast: a comprehensive review. *Histology and histopathology* **28**, 1393–1409 (2013).



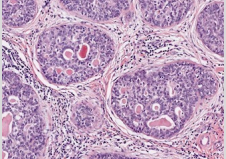
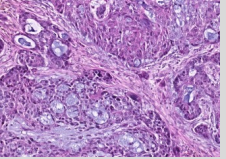
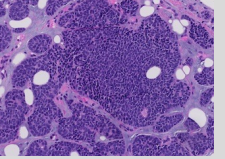
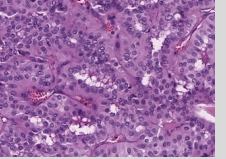
© AGO e. V.  
in der DGGG e.V.  
sowie  
in der DKG e.V.

Guidelines Breast  
Version 2024.1D

www.ago-online.de

FORSCHEN  
LEHREN  
HEILEN

## Rare and salivary-type TNBC: Tumors with divergent clinical behavior and specific genetic alterations

Adenoid-cystic carcinoma	Secretory carcinoma	Polymorphous carcinoma	Tall cell carcinoma with reversed polarity
			
<p><b>MYB-NFIB</b> <b>MYBL1 rearrangements</b> <b>MYB gene amplification</b></p>	<p><b>ETV6-NTRK3</b> <b>gene fusions</b></p>	<p><b>PRKD1 E710D</b> <b>PRKD1/PRKOZ/PRKD3</b> <b>rearrangements</b></p>	<p><b>IDH2 hotspot mutations</b></p>

### Adenoid-cystic carcinoma

1. Kim, J. et al. MYBL1 rearrangements and MYB amplification in breast adenoid cystic carcinomas lacking the MYB-NFIB fusion gene. *The Journal of Pathology* 244, 143–150 (2018).
2. Fusco, N. et al. Genetic events in the progression of adenoid cystic carcinoma of the breast to high-grade triple-negative breast cancer. *Modern Pathology* 29, 1292–1305 (2016).
3. Foschini, M. P. et al. Solid Variant of Adenoid Cystic Carcinoma of the Breast: A Case Series With Proposal of a New Grading System. *International Journal of Surgical Pathology* 24, 97–102 (2016).
4. Martelotto, L. G. et al. Genomic landscape of adenoid cystic carcinoma of the breast. *The Journal of Pathology* 237, 179–189 (2015).
5. Wetterskog, D. et al. Adenoid cystic carcinomas constitute a genomically distinct subgroup of triple-negative and basal-like breast cancers. *The Journal of Pathology* 226, 84–96 (2012).

### Secretory carcinoma

1. Amott, D. H., Masters, R. & Moore, S. Secretory carcinoma of the breast. *The breast journal* 12, 183 (2006).
2. Laé, M. et al. Secretory breast carcinomas with ETV6-NTRK3 fusion gene belong to the basal-like carcinoma spectrum. *Modern Pathology* 22, 291–298 (2008).
3. Skálová, A. et al. Mammary analogue secretory carcinoma of salivary glands, containing the ETV6-NTRK3 fusion gene: a hitherto

undescribed salivary gland tumor entity. *The American journal of surgical pathology* 34, 599–608 (2010).

4. Li, D. *et al.* Secretory breast carcinoma: a clinicopathological and immunophenotypic study of 15 cases with a review of the literature. *Modern Pathology* 25, 567–575 (2012).
5. Cabello, C. *et al.* Case report and review of the literature: secretory breast cancer in a 13-year-old boy--10 years of follow up. *Breast Cancer Research and Treatment* 133, 813–820 (2012).
6. Osako, T., Takeuchi, K., Horii, R., Iwase, T. & Akiyama, F. Secretory carcinoma of the breast and its histopathological mimics: value of markers for differential diagnosis. *Histopathology* 63, 509–519 (2013).
7. Lee, S. G. *et al.* Secretory breast carcinoma: A report of three cases and a review of the literature. *Oncology Letters* 8, 683–686 (2014).
8. Castillo, M. D. *et al.* Secretory Breast Carcinoma: A Histopathologic and Genomic Spectrum Characterized by a Joint Specific ETV6-NTRK3 Gene Fusion. *The American journal of surgical pathology* 39, 1458–1467 (2015).
9. Soyer, T. *et al.* Secretory breast carcinoma in a 6-year-old girl: mastectomy with sentinel lymph node dissection. *Pediatric surgery international* 31, 677–681 (2015).

#### Polymorphous carcinoma

1. Skálová, A. *et al.* The Role of Molecular Testing in the Differential Diagnosis of Salivary Gland Carcinomas. *Am J Surg Pathology* 42, e11–e27 (2018).
2. Asioli, S. *et al.* Polymorphous adenocarcinoma of the breast. Report of three cases. *Virchows Arch* 448, 29–34 (2006).

#### Tall cell carcinoma with reversed polarity

1. Chiang, S. *et al.* IDH2 Mutations Define a Unique Subtype of Breast Cancer with Altered Nuclear Polarity. *Cancer Research* 76, 7118–7129 (2016).
2. Tosi, A. L. *et al.* Breast Tumor Resembling the Tall Cell Variant of Papillary Thyroid Carcinoma: Report of 4 Cases With Evidence of Malignant Potential. *International Journal of Surgical Pathology* 15, 14–19 (2016).
3. Pitino, A., Squillaci, S., Spairani, C., Rattu, P. C. & Cosimi, M. F. Tall cell variant of papillary breast carcinoma: an additional case with review of the literature. *Pathologica* 109, 162–167 (2017).
4. Foschini, M. P. *et al.* Solid Papillary Breast Carcinomas Resembling the Tall Cell Variant of Papillary Thyroid Neoplasms: A Unique Invasive Tumor With Indolent Behavior. *The American journal of surgical pathology* 41, 887–895 (2017).
5. Bhargava, R. *et al.* Breast Tumor Resembling Tall Cell Variant of Papillary Thyroid Carcinoma: A Solid Papillary Neoplasm With



Characteristic Immunohistochemical Profile and Few Recurrent Mutations. *American journal of clinical pathology* 147, 399–410 (2017).

6. Alsadoun, N. *et al.* Solid papillary carcinoma with reverse polarity of the breast harbors specific morphologic, immunohistochemical and molecular profile in comparison with other benign or malignant papillary lesions of the breast: a comparative study of 9 additional cases. *Modern Pathology* 31, 1367–1380 (2018).
  7. Lozada, J. R. *et al.* Solid papillary breast carcinomas resembling the tall cell variant of papillary thyroid neoplasms (solid papillary carcinomas with reverse polarity) harbour recurrent mutations affecting IDH2 and PIK3CA: a validation cohort. *Histopathology* 73, 339–344 (2018).
  8. hong, E. *et al.* Breast Tumor Resembling the Tall Cell Variant of Papillary Thyroid Carcinoma: Molecular Characterization by Next-Generation Sequencing and Histopathological Comparison With Tall Cell Papillary Carcinoma of Thyroid. *International Journal of Surgical Pathology* 27, 1066896918800779–141 (2018).
  9. Asioli, S. & Ambrosi, F. Tall Cell Variant of Papillary Breast Carcinoma. in vol. 14 371–374 (Springer International Publishing, 2019).
- 
1. Zhong, E. *et al.* Breast Tumor Resembling the Tall Cell Variant of Papillary Thyroid Carcinoma: Molecular Characterization by Next-Generation Sequencing and Histopathological Comparison With Tall Cell Papillary Carcinoma of Thyroid. *International Journal of Surgical Pathology* 27, 1066896918800779–141 (2018).
  2. Castillo, M. D. *et al.* Secretory Breast Carcinoma: A Histopathologic and Genomic Spectrum Characterized by a Joint Specific ETV6-NTRK3 Gene Fusion. *The American journal of surgical pathology* 39, 1458–1467 (2015).
  3. Osako, T., Takeuchi, K., Horii, R., Iwase, T. & Akiyama, F. Secretory carcinoma of the breast and its histopathological mimics: value of markers for differential diagnosis. *Histopathology* 63, 509–519 (2013).
  4. Asioli, S. *et al.* Polymorphous adenocarcinoma of the breast. Report of three cases. *Virchows Arch* 448, 29–34 (2006).

## Befundung: Differenzierungsgrad

	Oxford		
	LoE	GR	AGO
▪ Anwendung des Nottingham-Grading (Elston & Ellis 1991) für alle Typen des invasiven Mammakarzinoms (auch nach neoadj. Therapie)	5	D	++
▪ Bei sehr wenig Tumorgewebe rein nukleäres Grading oder Heranziehung zusätzlicher Kriterien wie Ki-67 Proliferationsfraktion	5	D	++
▪ Grading des DCIS z.B. gemäß WHO-Klassifikation des Mammakarzinoms (5. Aufl., 2019)	5	D	++
▪ Wiedergabe des Tumorgrading zumindest auch numerisch (z.B. G3)	5	D	++

### Grading

1. Elston C, Ellis I. Pathological prognostic factors in breast cancer. I. The value of histological grade in breast cancer: experience from a large study with long-term follow-up. *Histopathology*. 1991;19(5):403-41
2. WHO. Breast Tumours: WHO Classification of Tumours. 5 ed. Lyon (France): International Agency for Research on Cancer; 2019
3. Christgen M, Länger F, Kreipe H. Histologisches Grading beim Mammakarzinom. *Der Pathologe*. 2016;37(4):328-336. doi:10.1007/s00292-016-0182-8.
4. Chang JM, McCullough AE, Dueck AC, et al. Back to Basics: Traditional Nottingham Grade Mitotic Counts Alone are Significant in Predicting Survival in Invasive Breast Carcinoma. *Ann Surg Oncol*. 2015;22 Suppl 3:S509-S515. doi:10.1245/s10434-015-4616-y.
5. Schwartz AM, Henson DE, Chen D, Rajamarthandan S. Histologic grade remains a prognostic factor for breast cancer regardless of the number of positive lymph nodes and tumor size: a study of 161 708 cases of breast cancer from the SEER Program. *Arch Pathol Lab Med*. 2014;138(8):1048-1052. doi:10.5858/arpa.2013-0435-OA.
6. Rakha EA, Reis-Filho JS, Baehner F, et al. Breast cancer prognostic classification in the molecular era: the role of histological grade. *Breast Cancer Res*. 2010;12(4):207. doi:10.1186/bcr2607.

7. Rakha EA, El-Sayed ME, Lee AHS, et al. Prognostic significance of Nottingham histologic grade in invasive breast carcinoma. *J Clin Oncol*. 2008;26(19):3153-3158. doi:10.1200/JCO.2007.15.5986.

#### Grading of invasive lobular carcinoma

1. Rakha EA, El-Sayed ME, Menon S, Green AR, Lee AHS, Ellis IO. Histologic grading is an independent prognostic factor in invasive lobular carcinoma of the breast. *Breast Cancer Res Treat*. 2008;111(1):121-127. doi:10.1007/s10549-007-9768-4.
2. Talman M-LM, Jensen M-B, Rank F. Invasive lobular breast cancer. Prognostic significance of histological malignancy grading. *Acta Oncol*. 2007;46(6):803-809. doi:10.1080/02841860601137397.
3. Bane AL, Tjan S, Parkes RK, Andrulis I, O'Malley FP. Invasive lobular carcinoma: to grade or not to grade. *Mod Pathol*. 2005;18(5).

## Befundung: Tumorgröße und gesamte Tumorausdehnung

	Oxford		
	LoE	GR	AGO
▪ <b>Invasive Tumorgröße, unter Berücksichtigung des makroskopischen und histologischen Befundes und klinisch-bildgebender Befunde</b>	5	D	++
▪ <b>Bei Satellitenherden und Multifokalität zusätzlich Gesamtausdehnung des invasiven Karzinoms</b>	5	D	++
▪ <b>Angabe der Ausdehnung der DCIS- oder LCIS-Komponente, wenn extensiv (mehr als das Doppelte der Ausdehnung des invasiven Karzinoms)</b>	5	D	++

### Determination of tumor size

1. Pritt, B., Tessitore, J. J., Weaver, D. L. et al (2005). The effect of tissue fixation and processing on breast cancer size. *Human Pathology*, 36(7), 756–760.
2. Varma, S., Ozerdem, U., & Hoda, S. A. (2014). Complexities and challenges in the pathologic assessment of size (T) of invasive breast carcinoma. *Advances in Anatomic Pathology*, 21(6), 420–432.

### Multifocality

1. Hilton, J. F., Bouganim, N., Dong, B., et al. (2013). Do alternative methods of measuring tumor size, including consideration of multicentric/multifocal disease, enhance prognostic information beyond TNM staging in women with early stage breast cancer: an analysis of the NCIC CTG MA.5 and MA.12 clinical trials. *Breast Cancer Research and Treatment*, 142(1), 143–151.
2. NHS (2005) Pathology Reporting of Breast Disease. IA Joint Document Incorporating the Third Edition of the NHS Breast Screening Programme's Guidelines for Pathology Reporting in Breast Cancer Screening and the Second Edition of The Royal College of Pathologists' Minimum Dataset for Breast Cancer Histopathology


<http://www.cancerscreening.nhs.uk/breastscreen/publications/nhsbsp58-low-resolution.pdf>

3. Perry N, Broeders M, de Wolf C, et al. European guidelines for quality assurance in breast cancer screening and diagnosis. Fourth edition--summary document. *Annals of Oncology*. 2008 Apr 1;19(4):614–22.
4. Tot, T., Gere, M., Pekár, G., et al. (2011). Breast cancer multifocality, disease extent, and survival. *Human Pathology*, 42(11), 1761–1769.

#### Extensive intraductal component (EIC)

1. Mai, K. T., Perkins, D. G., & Mirsky, D. (2003). Location and extent of positive resection margins and ductal carcinoma in situ in lumpectomy specimens of ductal breast carcinoma examined with a microscopic three-dimensional view. *The Breast Journal*, 9(1), 33–38.
2. Smitt, M. C., Nowels, K., Carlson, R. W., et al. (2003). Predictors of reexcision findings and recurrence after breast conservation. *International Journal of Radiation OncologyBiologyPhysics*, 57(4), 979–985
3. Schnitt, S. J., Connolly, J. L., Khettry, U., et al. (1987). Pathologic findings on re-excision of the primary site in breast cancer patients considered for treatment by primary radiation therapy. *Cancer*, 59(4), 675–681.
4. Sinn, H. P., Anton, H. W., Magener, A., et al. (1998). Extensive and predominant in situ component in breast carcinoma: their influence on treatment results after breast-conserving therapy. *European Journal of Cancer*, 34(5), 646–653

# Befundung: pTNM



Oxford

LoE	GR	AGO
5	D	++

## ■ Anwendung der aktuellen UICC-Klassifikation (8. Auflage)

- pT1–3:** Größter invasiver Tumorherd, nicht Gesamt-ausdehnung, Multifokalität od. Multizentrität
- pT4:** Alleinige Infiltration der Dermis nicht ausreichend. Kriterien für pT4a/b/c/d müssen erfüllt sein
- pT4d:** Eine negative Hautbiopsie schließt pT4d (inflammatorisches Karzinom) nicht aus
- pM:** pM1 bei jeglichem nicht regionärem Tumornachweis, ausgenommen kontralateralem Zweitkarzinom. Eine Angabe von MX od. pMX wird nicht empfohlen.

## TNM staging (7th ed.) according to UICC und AJCC

1. Wittekind C. *TNM - Klassifikation Maligner Tumoren 8. Aufl.* John Wiley & Sons; 2016.
2. Brierley JD, Gospodarowicz MK, Wittekind C. *TNM Classification of Malignant Tumours 8th ed.* John Wiley & Sons; 2016.
3. American-Joint-Committee-on-Cancer (2017) AJCC cancer staging manual 8<sup>th</sup> ed. Springer, New York; London
4. Amin MB, Greene FL, Edge SB, et al. The Eighth Edition AJCC Cancer Staging Manual: Continuing to build a bridge from a population-based to a more “personalized” approach to cancer staging. *CA Cancer J Clin.* 2017;67(2):93-99. doi:10.3322/caac.21388.

## pT4b category: Involvement of the skin

1. Wieland, A., Louwman, M., Voogd, A., et al. (2004). Determinants of prognosis in breast cancer patients with tumor involvement of the skin (pT4b). *The Breast Journal*, 10(2), 123–128. doi:21279 [pii]
2. Harms, K., & Wittekind, C. (2009). Prognosis of women with pT4b breast cancer: the significance of this category in the TNM system. *European Journal of Surgical Oncology : the Journal of the European Society of Surgical Oncology and the British Association of*

Surgical Oncology, 35(1), 38–42. doi:10.1016/j.ejso.2007.11.016

pT4d category: Inflammatory breast cancer

1. Yamauchi, H., Woodward, W. A., Valero, V., et al. (2012). Inflammatory breast cancer: what we know and what we need to learn. *The Oncologist*, 17(7), 891–899. doi:10.1634/theoncologist.2012-0039

## Befundung: Beurteilung der Resektionsränder, R-Klassifikation

	Oxford		
	LoE	GR	AGO
▪ Randsituation, makroskopisch Abstand zu allen Rändern und histologisch die nächsten < 1cm untersuchen	5	D	++
▪ Angabe des minimalen histologischen Sicherheitsabstandes und dessen Topographie	5	D	++
▪ R-Klassifikation	5	D	++
<b>R0:</b> Kein Residualtumor			
<b>R1:</b> Histologisch invasives oder nicht invasives Karzinom im Resektionsrand			
<b>RX:</b> Beurteilung des Resektionsrandes nicht möglich (z.B. Tumor in mehreren Teilpräparaten)			

### Pathological margin assessment

1. Schnitt, S. J., Moran, M. S., Houssami, N., et al. (2014). The Society of Surgical Oncology-American Society for Radiation Oncology Consensus Guideline on Margins for Breast-Conserving Surgery With Whole-Breast Irradiation in Stages I and II Invasive Breast Cancer: Perspectives for Pathologists. Archives of Pathology & Laboratory Medicine. doi:10.5858/arpa.2014-0384-ED
2. Houssami, N., & Morrow, M. (2014). Margins in breast conservation: a clinician's perspective and what the literature tells us. Journal of Surgical Oncology, 110(1), 2–7. doi:10.1002/jso.23594
3. Houssami, N., Macaskill, P., Marinovich, M. L., et al. (2014). The association of surgical margins and local recurrence in women with early-stage invasive breast cancer treated with breast-conserving therapy: a meta-analysis. Annals of Surgical Oncology, 21(3), 717–730.
4. Yeap, B. H., Muniandy, S., Lee, S.-K., et al. (2007). Specimen shrinkage and its influence on margin assessment in breast cancer. Asian Journal of Surgery / Asian Surgical Association, 30(3), 183–187. doi:10.1016/S1015-9584(08)60020-2
5. Dooley, W. C., & Parker, J. (2005). Understanding the mechanisms creating false positive lumpectomy margins. American Journal of Surgery, 190(4), 606–608. doi:10.1016/j.amjsurg.2005.06.023



6. Keskek, M., Kothari, M., Ardehali, B. et al. (2004). Factors predisposing to cavity margin positivity following conservation surgery for breast cancer. *European Journal of Surgical Oncology*, 30(10), 1058–1064. doi:10.1016/j.ejso.2004.07.019
7. Graham, R. A., Homer, M. J., Katz, J., et al. (2002). The pancake phenomenon contributes to the inaccuracy of margin assessment in patients with breast cancer. *American Journal of Surgery*, 184(2), 89–93.

#### R-Classifikation

1. Wittekind C, Compton C, Quirke P, et al. A uniform residual tumor (R) classification: integration of the R classification and the circumferential margin status. *Cancer*. 2009;115(15):3483-3488. doi:10.1002/cncr.24320.

## Befundung: Lymphgefäßinvasion

	Oxford		
	LoE	GR	AGO
<ul style="list-style-type: none"> <li>▪ <b>L1: Nachweis einer Lymphgefäßinvasion</b></li> <li><b>L0: Keine eindeutige Lymphgefäßinvasion</b></li> </ul>	5	D	++
<ul style="list-style-type: none"> <li>▪ <b>IHC zum Nachweis einer Lymphgefäßinvasion</b></li> </ul>	3b	C	-
<ul style="list-style-type: none"> <li>▪ <b>Unterscheide: peritumorale und ausgedehnte Lymphgefäßinvasion</b></li> </ul>	3b	C	++
<ul style="list-style-type: none"> <li>▪ <b>Angabe der Blutgefäßinvasion (V0/V1) fakultativ, da prognostische Relevanz unklar</b></li> </ul>	5	D	+

### Definition of L- and V-Classification

1. Wittekind C. *TNM - Klassifikation Maligner Tumoren 8. Aufl.* John Wiley & Sons; 2016.

### Detection of angioinvasion

1. Manfrin, E., Remo, A., Pancione, M. et al. (2014). Comparison between invasive breast cancer with extensive peritumoral vascular invasion and inflammatory breast carcinoma: a clinicopathologic study of 161 cases. *American Journal of Clinical Pathology*, 142(3), 299–306. doi:10.1309/AJCPOXKX67KRAOVM
2. Ren, S., Abuel-Haija, M., Khurana, J. S., et al. (2011). D2-40: an additional marker for myoepithelial cells of breast and the precaution in interpreting tumor lymphovascular invasion. *International Journal of Clinical and Experimental Pathology*, 4(2), 175–182.
3. Van den Eynden, G. G., Van der Auwera, I., Van Laere, S. et al. (2006). Distinguishing blood and lymph vessel invasion in breast cancer: a prospective immunohistochemical study. *British Journal of Cancer*, 94(11), 1643–1649.
4. Zaorsky, N. G., Patil, N., Freedman, G. M., et al. (2012). Differentiating lymphovascular invasion from retraction artifact on histological specimen of breast carcinoma and their implications on prognosis. *Journal of Breast Cancer*, 15(4), 478–480.

### Prognostic significance of lymphovascular invasion

1. Gujam, F. J. A., Going, J. J., Edwards, J. et al. (2014). The role of lymphatic and blood vessel invasion in predicting survival and methods of detection in patients with primary operable breast cancer. *Critical Reviews in Oncology/Hematology*, 89(2), 231–241. doi:10.1016/j.critrevonc.2013.08.014
2. Colleoni, M., Rotmensz, N., Maisonneuve, P., et al. (2007). Prognostic role of the extent of peritumoral vascular invasion in operable breast cancer. *Annals of Oncology*, 18(10), 1632–1640
3. Rakha, E. A., Martin, S., Lee, A. H. S., et al. (2011). The prognostic significance of lymphovascular invasion in invasive breast carcinoma. *Cancer*, 118(15), 3670–3680.

## Befundung: Evaluation tumor-infiltrierender Lymphozyten (TIL)

Oxford		
LoE	GR	AGO
5	D	+/-

- Identifikation von Tumoren mit prädominatem lymphozytärem Infiltrat (> 50%) im Tumorstroma (n. Salgado et al.\*)

Nur das intratumorale Infiltrat im Stroma und nicht an der Invasionsfront berücksichtigen

Zentrale Fibrose- und Nekrosezonen nicht bewerten

Durchschnittswert des lymphozytären Infiltrates in Prozent angeben

- \* Salgado, R., Denkert, C., Demaria, S., Sirtaine, N., Klauschen, F., Pruneri, G., et al. (2014). The evaluation of tumor-infiltrating lymphocytes (TILs) in breast cancer: recommendations by an International TILs Working Group 2014. *Annals of Oncology*

### Definition and impact of predominant lymphocytic infiltration

1. Kos Z, Roblin E, Kim RS, et al. Pitfalls in assessing stromal tumor infiltrating lymphocytes (sTILs) in breast cancer. *npj Breast Cancer*. 2020;6(1):17–16. doi:10.1038/s41523-020-0156-0.
2. Dieci MV, Radosevic-Robin N, Fineberg S, et al. Update on tumor-infiltrating lymphocytes (TILs) in breast cancer, including recommendations to assess TILs in residual disease after neoadjuvant therapy and in carcinoma in situ: A report of the International Immuno-Oncology Biomarker Working Group on Breast Cancer. *Semin Cancer Biol*. 2018;52(Pt 2):16-25. doi:10.1016/j.semancer.2017.10.003.
3. Grigoriadis A, Gazinska P, Pai T, et al. Histological scoring of immune and stromal features in breast and axillary lymph nodes is prognostic for distant metastasis in lymph node-positive breast cancers. *J Pathol Clin Res*. 2018;4(1):39-54. doi:10.1002/cjp2.87.
4. Tramm T, Di Caterino Tina, Jylling A-MB, et al. Standardized assessment of tumor-infiltrating lymphocytes in breast cancer: an evaluation of inter-observer agreement between pathologists. *Acta Oncol*. 2018;57(1):90-94. doi:10.1080/0284186X.2017.1403040.
5. Denkert C, Minckwitz von G, Darb-Esfahani S, et al. Tumour-infiltrating lymphocytes and prognosis in different subtypes of breast cancer: a pooled analysis of 3771 patients treated with neoadjuvant therapy. *Lancet Oncol*. 2018;19(1):40-50. doi:10.1016/S1470-2045(17)30904-X.

6. Salgado R, Denkert C, Demaria S, et al. The evaluation of tumor-infiltrating lymphocytes (TILs) in breast cancer: recommendations by an International TILs Working Group 2014. *Ann Oncol*. 2015;26(2):259-271. doi:10.1093/annonc/mdu450.
7. Denkert C, Salgado R, Demaria S. Standardized evaluation of Tumor-Infiltrating Lymphocytes (TIL) in Breast Cancer for daily clinical and research practice or clinical trial setting. In:; 2014:1-14.

## Befundung: nach neoadjuvanter Chemotherapie

	Oxford		
	LoE	GR	AGO
▪ Identifikation des Tumorbetts, sonst ypTX	4	D	++
▪ Angabe der Tumorgröße als max. Tumorbettgröße mit vitalem, invasiven Ca.	4	D	++
▪ pCR definiert als Fehlen invasiven Karzinoms sowie Abwesenheit von Gefäßinvasion und Lymphknotenmetastasen. Vorhandensein von pTis ist anzugeben.	2b	D	+
▪ IHC zum Nachweis minimalen Residualtumors (LK)	2b	B	+/-
▪ Angabe von ypTN-Status nach neoadj. Therapie	5	D	++
▪ Erneute Bestimmung der Hormonrezeptoren und des HER2-Status am Residualtumor	5	D	+/-
▪ Intraoperativer Schnellschnitt (verminderte Sensitivität)	5	D	-
▪ Tumorregression-Scores: RCB-Score oder Sataloff-Score	4	D	+/-

### Specimen processing after neoadjuvant chemotherapy

1. Provenzano E, Bossuyt V, Viale G, et al. Standardization of pathologic evaluation and reporting of postneoadjuvant specimens in clinical trials of breast cancer: recommendations from an international working group. *Mod Pathol.* 2015;28(9):1185-1201. doi:10.1038/modpathol.2015.74
2. Bossuyt V, Provenzano E, Symmans WF, et al. Recommendations for standardized pathological characterization of residual disease for neoadjuvant clinical trials of breast cancer by the BIG-NABCG collaboration. *Ann Oncol.* 2015;26(7):1280-1291. doi:10.1093/annonc/mdv161
3. Sahoo S, Lester SC. Pathology of breast carcinomas after neoadjuvant chemotherapy: an overview with recommendations on specimen processing and reporting. *Arch Pathol Lab Med.* 2009;133(4):633-642. doi:10.1043/1543-2165-133.4.633
4. Fan F. Evaluation and reporting of breast cancer after neoadjuvant chemotherapy. *Open Pathology Journal.* 2009;3:58-63
5. Gralow JR, Burstein HJ, Wood W, et al. Preoperative therapy in invasive breast cancer: pathologic assessment and systemic therapy issues in operable disease. *J Clin Oncol.* 2008;26(5):814-819. doi:10.1200/JCO.2007.15.3510
6. Pinder SE, Provenzano E, Earl H, Ellis IO. Laboratory handling and histology reporting of breast specimens from patients who have

received neoadjuvant chemotherapy. *Histopathology*. 2007;50(4):409-417. doi:10.1111/j.1365-2559.2006.02419.x.

#### RCB-Score

1. RCB-Calculator: <http://www3.mdanderson.org/app/medcalc/index.cfm?pagename=jsconvert>
2. Bossuyt V, Symmans WF. Standardizing of Pathology in Patients Receiving Neoadjuvant Chemotherapy. *Ann Surg Oncol*. 2016;23(10):3153-3161. doi:10.1245/s10434-016-5317-x
3. Naidoo K, Parham DM, Pinder SE. An Audit of Residual Cancer Burden Reproducibility in a UK context. *Histopathology*. August 2016. doi:10.1111/his.13054
4. Peintinger F, Sinn B, Hatzis C, et al. Reproducibility of residual cancer burden for prognostic assessment of breast cancer after neoadjuvant chemotherapy. *Mod Pathol*. 2015;28(7):913-920. doi:10.1038/modpathol.2015.53
5. Sheri A, Smith IE, Johnston SR, et al. Residual proliferative cancer burden to predict long-term outcome following neoadjuvant chemotherapy. *Ann Oncol*. 2015;26(1):75-80. doi:10.1093/annonc/mdu508
6. Symmans, W. F., Peintinger, F., Hatzis, C., et al. (2007). Measurement of residual breast cancer burden to predict survival after neoadjuvant chemotherapy. *Journal of Clinical Oncology : Official Journal of the American Society of Clinical Oncology*, 25(28), 4414–4422.

#### Sataloff-Score

1. Sataloff DM, Mason BA, Prestipino AJ, Seinige UL, Lieber CP, Baloch Z. Pathologic response to induction chemotherapy in locally advanced carcinoma of the breast: a determinant of outcome. *J Am Coll Surg*. 1995;180(3):297-306.

## Prädiktive Pathologie der endokrinen Responsivität

- **Immunhistochemische Detektion des Östrogen- und Progesteronrezeptors am Paraffinschnitt mit Angabe des Prozentsatzes positiver Tumorzellkerne (ER positiv bei  $\geq 1\%$ ; niedrig positiv bei  $\geq 1\%$  bis  $10\%$ , PR positiv bei  $\geq 10\%$ )**
- **Nachweis endokriner Responsivität durch Ki67 Abfall auf  $\leq 10\%$  nach 3-4 wöchiger präoperativer endokriner Therapie bei Erstdiagnose**
- **Nachweis sekundärer (unter endokriner Therapie erworbener) endokriner Resistenz durch Untersuchung der aktivierenden *ESR1* Mutation in der Liquid Biopsy oder den Metastasen**

Oxford		
LoE	GR	AGO
1a	A	++
1b	A	+
1b	A	+

### ASCO/CAP Guideline for ER- and PR-testing

1. Allison KH, Hammond MEH, Dowsett M, et al. Estrogen and Progesterone Receptor Testing in Breast Cancer: ASCO/CAP Guideline Update. *J Clin Oncol.* 2020;38(12):JCO1902309–1366. doi:10.1200/JCO.19.02309
2. Duffy MJ, Harbeck N, Nap M, et al. Clinical use of biomarkers in breast cancer: Updated guidelines from the European Group on Tumor Markers (EGTM). *Eur J Cancer.* 2017;75:284-298. doi:10.1016/j.ejca.2017.01.017.

### IHC-testing for ER-positivity

1. Duffy MJ, Harbeck N, Nap M, et al. Clinical use of biomarkers in breast cancer: Updated guidelines from the European Group on Tumor Markers (EGTM). *Eur J Cancer.* 2017;75:284-298. doi:10.1016/j.ejca.2017.01.017.
2. Schrijver WAME, Suijkerbuijk KPM, van Gils CH, van der Wall E, Moelans CB, van Diest PJ. Receptor Conversion in Distant Breast Cancer Metastases: A Systematic Review and Meta-analysis. *J Natl Cancer Inst.* 2018;110(6):568-580. doi:10.1093/jnci/djx273.
3. Traub L, Thill M, Nitschmann S. 20-Jahres-Ergebnisse einer 5-jährigen Hormontherapie bei Mammakarzinom : Early Breast Cancer Trialists' Collaborative Group (EBCTCG). *Internist (Berl).* 2018;59(4):410-412. doi:10.1007/s00108-018-0398-1.



4. Allred, D. C. (2010). Issues and updates: evaluating estrogen receptor-alpha, progesterone receptor, and HER2 in breast cancer. *Modern Pathology*, 23 Suppl 2, S52–9. doi:10.1038/modpathol.2010.55
5. Allred, D. C., Carlson, R. W., Berry, D. A., et al. (2009). NCCN Task Force Report: Estrogen Receptor and Progesterone Receptor Testing in Breast Cancer by Immunohistochemistry. *Journal of the National Comprehensive Cancer Network*, 7 Suppl 6, S1–S21– quiz S22–3. Retrieved from [http://www.nccn.org/JNCCN/PDF/2009\\_estrogen\\_receptor\\_and\\_progesterone\\_receptor\\_immunohistochemistry.pdf](http://www.nccn.org/JNCCN/PDF/2009_estrogen_receptor_and_progesterone_receptor_immunohistochemistry.pdf)
6. Gown, A. M. (2008). Current issues in ER and HER2 testing by IHC in breast cancer. *Modern Pathology*, 21, S8–S15
7. Hammond, M. E., Hayes, D. F., & Wolff, A. C. (2011). Clinical Notice for American Society of Clinical Oncology-College of American Pathologists Guideline Recommendations on ER/PgR and HER2 Testing in Breast Cancer. *Journal of Clinical Oncology : Official Journal of the American Society of Clinical Oncology*, 29(15), e458–e458.
8. Cheang MC, Treaba DO, Speers CH, et al. Immunohistochemical detection using the new rabbit monoclonal antibody SP1 of estrogen receptor in breast cancer is superior to mouse monoclonal antibody 1D5 in predicting survival. *J Clin Oncol*. 2006 Dec 20;24(36):5637-44. Epub 2006 Nov 20.
9. Hammond et al. American Society of Clinical Oncology/College of American Pathologists guideline recommendations for immunohistochemical testing of estrogen and progesterone receptors in breast cancer. *Arch Pathol Lab Med* (2010) vol. 134 (6) pp. 907-22
10. Rocha R, Nunes C, Rocha G et al. Rabbit monoclonal antibodies show higher sensitivity than mouse monoclonals for estrogen and progesterone receptor evaluation in breast cancer by immunohistochemistry. *Pathol Res Pract*. 2008;204(9):655-62. Epub 2008 Jun 18.

### IHC Scores

1. Allred, D. C., Harvey, J. M., Berardo, M., et al. (1998). Prognostic and predictive factors in breast cancer by immunohistochemical analysis. *Modern Pathology*, 11(2), 155–168.
2. Remmele, W., & Stegner, H. (1987). Vorschlag zur einheitlichen Definition eines Immunreaktiven Score (IRS) für den immunhistochemischen Östrogenrezeptor-Nachweis (ER-ICA) im Mammakarzinomgewebe. *Der Pathologe*, 8(3), 138–140.

### Monoclonal Antibodies for ER-Testing

1. Cheang MC, Treaba DO, Speers CH, et al. Immunohistochemical detection using the new rabbit monoclonal antibody SP1 of estrogen receptor in breast cancer is superior to mouse monoclonal antibody 1D5 in predicting survival. *J Clin Oncol.* 2006 Dec 20;24(36):5637-44.

### Niedrig positiv, ER 1%-10%

1. Deyarmin, B. et al. Effect of ASCO/CAP guidelines for determining ER status on molecular subtype. *Annals of Surgical Oncology* 20, 87–93 (2013).
2. Prabhu, J. S. et al. A Majority of Low (1-10%) ER Positive Breast Cancers Behave Like Hormone Receptor Negative Tumors. *Journal of Cancer* 5, 156–165 (2014).
3. Sanford, R. A. et al. High incidence of germline BRCA mutation in patients with ER low-positive/PR low-positive/HER-2 neu negative tumors. *Cancer* 121, 3422–3427 (2015).
4. Yi M, Huo L, Koenig KB, Mittendorf EA, Meric-Bernstam F, Kuerer HM, Bedrosian I, Buzdar AU, Symmans WF, Crow JR, Bender M, Shah RR, Hortobagyi GN, Hunt KK. Which threshold for ER positivity? a retrospective study based on 9639 patients. *Ann Oncol.* 2014 May;25(5):1004-11. doi: 10.1093/annonc/mdu053

### Primäre endokrine Resistenz

1. Tryfonidis K, Zardavas D, Katzenellenbogen BS, Piccart M. Endocrine treatment in breast cancer: Cure, resistance and beyond. *Cancer Treat Rev.* 2016 Nov;50:68-81. doi: 10.1016/j.ctrv.2016.08.008

2. Nitz UA, Gluz O, Kümmel S, Christgen M, Braun M, Aktas B, Lüdtke-Heckenkamp K, Forstbauer H, Grischke EM, Schumacher C, Darsow M, Krauss K, Nuding B, Thill M, Potenberg J, Uleer C, Warm M, Fischer HH, Malter W, Hauptmann M, Kates RE, Gräser M, Würstlein R, Shak S, Baehner F, Kreipe HH, Harbeck N. Endocrine Therapy Response and 21-Gene Expression Assay for Therapy Guidance in HR+/HER2- Early Breast Cancer. *J Clin Oncol*. 2022 Aug 10;40(23):2557-2567. doi: 10.1200/JCO.21.02759
3. Bliss JM, Tovey H, Evans A, et al; POETIC Trialists. Clinico-pathologic relationships with Ki67 and its change with short-term aromatase inhibitor treatment in primary ER + breast cancer: further results from the POETIC trial (CRUK/07/015). *Breast Cancer Res*. 2023 Apr 12;25(1):39. doi: 10.1186/s13058-023-01626-3.

#### Sekundäre endokrine Resistenz durch *ESR1* Mutation

1. Bidard FC, Kaklamani VG, Neven P, et al. Elacestrant (oral selective estrogen receptor degrader) Versus Standard Endocrine Therapy for Estrogen Receptor-Positive, Human Epidermal Growth Factor Receptor 2-Negative Advanced Breast Cancer: Results From the Randomized Phase III EMERALD Trial. *J Clin Oncol*. 2022 Oct 1;40(28):3246-3256. doi: 10.1200/JCO.22.00338.
2. Wong NZH, Yap DWT, Ong RJM, et al. Efficacy of Oral SERDs in the treatment of ER+, HER2 - metastatic breast cancer, a stratified analysis of the *ESR1* wild type and mutant subgroups. *Ann Oncol*. 2023 Oct 21:S0923-7534(23)04328-4. doi: 10.1016/j.annonc.2023.10.122.
3. Grote I, Poppe A, Lehmann U, Christgen M, Kreipe H, Bartels S. Frequency of genetic alterations differs in advanced breast cancer between metastatic sites. *Genes Chromosomes Cancer*. 2024 Jan;63(1):e23199. doi: 10.1002/gcc.23199.

## HER2-Bestimmung mittels IHC

	Oxford		
	LoE	GR	AGO
▪ <b>3+ Färbemuster: HER2 + wenn starke komplette zirkuläre Membranfärbung von &gt; 10% invasiver Zellen</b>	1a	A	++
▪ <b>2+ Färbemuster: Wenn &gt; 10% zirkuläre, schwache/mäßige Membranfärbung oder ≤ 10% stark, U-förmig bei mikropapillären Ca.: ISH erforderlich (CISH, SISH, FISH)</b>	1a	A	++
▪ <b>1+ Färbemuster: bei &gt;10% unvollständiger Membranfärbung, die schwach oder kaum wahrnehmbar ist</b>	1a	A	+
▪ <b>0 Färbemuster: Nachbestimmung bei Möglichkeit der Applikation von Trastuzumab-Deruxtecan*</b>	5	D	+
▪ <b>HER2-low: 1+ oder 2+ /ISH negativ</b>	1b	A	++

\* Wegen Heterogenität und Therapierelevanz

### ASCO/CAP Guideline on HER2-Testing

1. Wolff AC, Hammond MEH, Allison KH, et al. Human Epidermal Growth Factor Receptor 2 Testing in Breast Cancer: American Society of Clinical Oncology/College of American Pathologists Clinical Practice Guideline Focused Update. *Arch Pathol Lab Med.* May 2018;arpa.2018-0902-SA. doi:10.5858/arpa.2018-0902-SA.

### IHC and molecular HER2-Testing

1. Liu Z-H, Wang K, Lin D-Y, et al. Impact of the updated 2018 ASCO/CAP guidelines on HER2 FISH testing in invasive breast cancer: a retrospective study of HER2 fish results of 2233 cases. *Breast Cancer Res Treat.* 2019;175(1):51-57. doi:10.1007/s10549-019-05148-5.
2. Prat A, Pascual T, De Angelis C, et al. HER2-enriched subtype and ERBB2 expression in HER2-positive breast cancer treated with dual HER2 blockade. *J Natl Cancer Inst.* April 2019. doi:10.1093/jnci/djz042.
3. Gordian-Arroyo AM, Zynger DL, Tozbikian GH. Impact of the 2018 ASCO/CAP HER2 Guideline Focused Update. *Am J Clin Pathol.* 2019;152(1):17-26. doi:10.1093/ajcp/aqz012.
4. Curado M, Caramelo AS, Eloy C, Polónia A. What to expect from the 2018 ASCO/CAP HER2 guideline in the reflex in situ hybridization

test of immunohistochemically equivocal 2+ cases? *Virchows Arch*. 2019;68(6):394-399. doi:10.1007/s00428-019-02567-z.

5. Schneider F, Jin Y, Van Smaalen K, Gulbahce EH, Factor RE, Li X. The FDA-Approved Breast Cancer HER2 Evaluation Kit (HerceptTest; Dako) May Miss Some HER2-Positive Breast Cancers. *Am J Clin Pathol*. 2019;151(5):504-510. doi:10.1093/ajcp/aqy171.
6. Press MF, Seoane JA, Curtis C, et al. Assessment of ERBB2/HER2 Status in HER2-Equivocal Breast Cancers by FISH and 2013/2014 ASCO-CAP Guidelines. *JAMA Oncol*. 2019;5(3):366-375. doi:10.1001/jamaoncol.2018.6012.
7. Rye IH, Trinh A, Saetersdal AB, et al. Intratumor heterogeneity defines treatment-resistant HER2+ breast tumors. *Molecular Oncology*. 2018;12(11):1838-1855. doi:10.1002/1878-0261.12375.
8. Dodson A, Parry S, Ibrahim M, et al. Breast cancer biomarkers in clinical testing: analysis of a UK national external quality assessment scheme for immunocytochemistry and in situ hybridisation database containing results from 199 300 patients. *J Pathol Clin Res*. 2018;4(4):262-273. doi:10.1002/cjp2.112.
9. Pfitzner BM, Lederer B, Lindner J, et al. Clinical relevance and concordance of HER2 status in local and central testing-an analysis of 1581 HER2-positive breast carcinomas over 12 years. *Mod Pathol*. 2018;31(4):607-615. doi:10.1038/modpathol.2017.171.
10. Sorscher S. Reclassifying HER2-equivocal disease. *Breast Cancer Res Treat*. 2018;167(3):823-823. doi:10.1007/s10549-017-4545-5.
11. Tong Y, Chen X, Fei X, et al. Can breast cancer patients with HER2 dual-equivocal tumours be managed as HER2-negative disease? *Eur J Cancer*. 2018;89:9-18. doi:10.1016/j.ejca.2017.10.033.
12. Petrelli F, Tomasello G, Barni S, Lonati V, Passalacqua R, Ghidini M. Clinical and pathological characterization of HER2 mutations in human breast cancer: a systematic review of the literature. *Breast Cancer Res Treat*. 2017;166(2):339-349. doi:10.1007/s10549-017-4419-x.
13. Hou Y, Nitta H, Wei L, et al. HER2 intratumoral heterogeneity is independently associated with incomplete response to anti-HER2 neoadjuvant chemotherapy in HER2-positive breast carcinoma. *Breast Cancer Res Treat*. 2017;166(2):447-457. doi:10.1007/s10549-017-4453-8.

## HER2-low

1. Rosso, C. & Voutsadakis, I. A. Characteristics, Clinical Differences and Outcomes of Breast Cancer Patients with Negative or Low HER2 Expression. *Clin Breast Cancer* **22**, 391–397 (2022).
2. Xu, K. *et al.* Discordance between IHC and ERBB2 mRNA to Determine HER2 Low Status for Breast Cancer. *J Mol Diagnostics* (2022) doi:10.1016/j.jmoldx.2022.04.002.
3. Zhang, G. *et al.* Distinct clinical and somatic mutational features of breast tumors with high-, low-, or non-expressing human epidermal growth factor receptor 2 status. *BMC Med* **20**, 142 (2022).
4. Tarantino, P. *et al.* Evolution of low HER2 expression between early and advanced-stage breast cancer. *Eur J Cancer* **163**, 35–43 (2022).
5. Fernandez, A. I. *et al.* Examination of Low ERBB2 Protein Expression in Breast Cancer Tissue. *JAMA Oncol* **8**, 1–4 (2022).
6. Zhang, H., Katerji, H., Turner, B. M., Audeh, W. & Hicks, D. G. HER2-low breast cancers: incidence, HER2 staining patterns, clinicopathologic features, MammaPrint and Blueprint genomic profiles. *Modern Pathol* 1–8 (2022) doi:10.1038/s41379-022-01019-5.
7. Chen, M. *et al.* Prognostic values of clinical and molecular features in HER2 low-breast cancer with hormonal receptor overexpression: features of HER2-low breast cancer. *Breast Cancer-tokyo* 1–10 (2022) doi:10.1007/s12282-022-01364-y.
8. Atallah, N. M. *et al.* Refining the definition of HER2 low class in invasive breast cancer. *Histopathology* (2022) doi:10.1111/his.14780.
9. Denkert, C. *et al.* Clinical and molecular characteristics of HER2-low-positive breast cancer: pooled analysis of individual patient data from four prospective, neoadjuvant clinical trials. *Lancet Oncol* **22**, 1151–1161 (2021).
10. Schettini, F. *et al.* Clinical, pathological, and PAM50 gene expression features of HER2-low breast cancer. *Npj Breast Cancer* **7**, 1 (2021).
11. Agostinetti, E. *et al.* HER2-Low Breast Cancer: Molecular Characteristics and Prognosis. *Cancers* **13**, 2824 (2021).
12. Gampenrieder, S. P. *et al.* Landscape of HER2-low metastatic breast cancer (MBC): results from the Austrian AGMT\_MBC-Registry. *Breast Cancer Res Bcr* **23**, 112 (2021).
13. Moutafi M. *et al.* Quantitative measurement of HER2 expression to subclassify ERBB2 unamplified breast cancer. *Lab Invest*. 2022 Oct;102(10):1101-1108.
14. Tarrantino P. *et al.* HER2-Low Breast Cancer: Pathological and Clinical Landscape. *J Clin Oncol*. 2020 Jun 10;38(17):1951-1962
15. Dabbs DJ, Huang RS, Ross JS. Novel markers in breast pathology. *Histopathology*. 2023 Jan;82(1):119-139.
16. Peiffer DS, Zhao F, Chen N, *et al.* Clinicopathologic Characteristics and Prognosis of ERBB2-Low Breast Cancer Among Patients in the National Cancer Database. *JAMA Oncol*. 2023 Apr 1;9(4):500-510. doi: 10.1001/jamaoncol.2022.7476.
17. Robbins CJ, Fernandez AI, Han G, *et al.* Multi-institutional Assessment of Pathologist Scoring HER2 Immunohistochemistry. *Mod*

Pathol. 2023 Jan;36(1):100032. doi: 10.1016/j.modpat.2022

## HER2-Bestimmung: ISH bei IHC 2+

	Oxford		
	LoE	GR	AGO
<ul style="list-style-type: none"> <li>▪ <b>Einfärben In-Situ-Hybridisierung (ISH):</b> <ul style="list-style-type: none"> <li>▪ HER2 + wenn <math>\geq 6</math> Signale in mindestens 20 kohäsiven Zellen</li> <li>▪ negativ bei <math>&lt; 4</math> Signalen/Kern</li> <li>▪ 2-Farben ISH empfohlen bei <math>\geq 4</math> und <math>&lt; 6</math> Signalen / Kern</li> </ul> </li> </ul>	3a	C	++
<ul style="list-style-type: none"> <li>▪ <b>Zweifarben In-Situ-Hybridisierung (ISH):</b> <ul style="list-style-type: none"> <li>▪ Gruppe 1: Ratio <math>\geq 2.0</math> und HER2-Signals/Kern <math>\geq 4.0</math> -&gt; HER2+</li> <li>▪ Gruppe 2: Ratio <math>\geq 2.0</math> und HER2-Signals/Kern <math>&lt; 4.0</math> -&gt; HER2- (kein Nutzen einer anti-HER2 Therapie)</li> <li>▪ Gruppe 3: Ratio <math>&lt; 2.0</math> und HER2-Signals/Kern <math>\geq 6.0</math> -&gt; HER2+ (Nutzen einer anti-HER2 Therapie jedoch unklar)</li> <li>▪ Gruppe 4: Ratio <math>&lt; 2.0</math> und HER2-Signals/Kern <math>\geq 4.0</math> und <math>&lt; 6</math> -&gt; HER2- (kein Nutzen einer anti-HER2 Therapie)</li> <li>▪ Gruppe 5: Ratio <math>&lt; 2.0</math> und HER2-Signals/Kern <math>&lt; 4.0</math> -&gt; HER2-</li> </ul> </li> </ul>	3a	D	++

### ASCO/CAP Guideline on HER2-Testing

1. Wolff AC, Hammond MEH, Allison KH, et al. Human Epidermal Growth Factor Receptor 2 Testing in Breast Cancer: American Society of Clinical Oncology/College of American Pathologists Clinical Practice Guideline Focused Update. *Arch Pathol Lab Med.* May 2018;arpa.2018-0902-SA. doi:10.5858/arpa.2018-0902-SA.

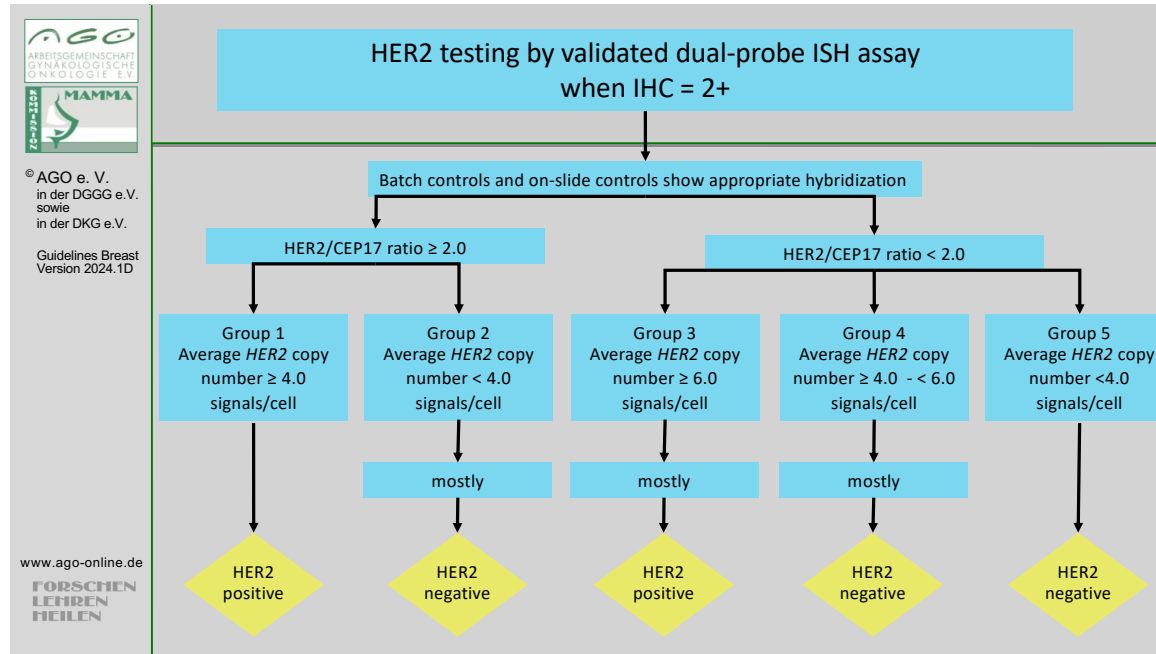
### ISH HER2-Testing

1. Hwang HC, Gown AM. Evaluation of Human Epidermal Growth Factor Receptor 2 (HER2) Gene Status in Human Breast Cancer Formalin-Fixed Paraffin-Embedded (FFPE) Tissue Specimens by Fluorescence In Situ Hybridization (FISH). *Methods Mol Biol.* 2016;1406(Chapter 5):61-70. doi:10.1007/978-1-4939-3444-7\_5.
2. Stoss OC, Scheel A, Nagelmeier I, et al. Impact of updated HER2 testing guidelines in breast cancer--re-evaluation of HERA trial fluorescence in situ hybridization data. *Mod Pathol.* 2015;28(12):1528-1534. doi:10.1038/modpathol.2015.112.
3. Starczynski J, Atkey N, Connelly Y, et al. HER2 gene amplification in breast cancer: a rogues' gallery of challenging diagnostic cases: UKNEQAS interpretation guidelines and research recommendations. *Am J Clin Pathol.* 2012;137(4):595-605.



doi:10.1309/AJCPATBZ2JFN1QQC.

4. Sauter G, Lee J, Bartlett JMS, Slamon DJ, Press MF. Guidelines for Human Epidermal Growth Factor Receptor 2 Testing: Biologic and Methodologic Considerations. *J Clin Oncol*. 2009;27(8):1323-1333. doi:10.1200/JCO.2007.14.8197.
5. Chivukula M, Bhargava R, Brufsky A, Surti U, Dabbs D. Clinical importance of HER2 immunohistologic heterogeneous expression in core-needle biopsies vs resection specimens for equivocal (immunohistochemical score 2+) cases. *Mod Pathol*. 2008;21(4):363-368. doi:10.1038/modpathol.3801021.



### ASCO/CAP Guideline on HER2-Testing

1. Wolff AC, Hammond MEH, Allison KH, et al. Human Epidermal Growth Factor Receptor 2 Testing in Breast Cancer: American Society of Clinical Oncology/College of American Pathologists Clinical Practice Guideline Focused Update. *Arch Pathol Lab Med*. May 2018;arpa.2018-0902-SA. doi:10.5858/arpa.2018-0902-SA.



© AGO e. V.  
in der DGGG e.V.  
sowie  
in der DKG e.V.

Guidelines Breast  
Version 2024.1D

www.ago-online.de

FORSCHEN  
LEBEN  
HEILEN

## HER2 Testing on Core Biopsies

**False positive immunohistochemical labeling may occur in core biopsies.**

**Therefore, methods of individual laboratories should be validated by comparison of core biopsies and resection specimens. Background staining should be evaluated by comparison with normal duct epithelium.**

**Alternatively, all G1 and G2 cases with HER2 3+ in core biopsies may be analyzed by ISH or may be re-evaluated in the resection specimen.**

**False positivity is likely when HER+ was reported in G1 tumors of the following types: Infiltrating ductal or lobular carcinoma, ER and PR positive, Tubular (at least 90% pure), Mucinous (at least 90% pure) Cribriform (at least 90% pure), Adenoid cystic carcinoma (90% pure).**

**In case of discrepancy between core biopsy and specimen, the HER2 overexpressing sample should be re-evaluated by a different method. If still discrepancy – anti-HER2-treatment if amplified in one of both samples. Expected rate of HER2-overexpression: 15% HER2 positive**

### ASCO/CAP Guideline on HER2-Testing

1. Wolff AC, Hammond MEH, Allison KH, et al. Human Epidermal Growth Factor Receptor 2 Testing in Breast Cancer: American Society of Clinical Oncology/College of American Pathologists Clinical Practice Guideline Focused Update. *Arch Pathol Lab Med*. May 2018:arpa.2018-0902-SA. doi:10.5858/arpa.2018-0902-SA.

## Zusätzliche Untersuchungen: Molekulare Bestimmung von HER2

- Therapieentscheidungen sollten nur auf IHC und ISH basieren
- Bestimmung des HER2-Status durch validierte Genexpressions-Testkits
- Bestimmung der HER2-Amplifikation durch NGS
- Verwendung der molekularen HER2-Bestimmung zur Subtypisierung

Oxford		
LoE	GR	AGO
1a	A	++
3b	B	-
5	D	-
3b	B	+/-

### Genomic and gene expression analysis of HER2

1. Prat A, Pascual T, De Angelis C, et al. HER2-enriched subtype and ERBB2 expression in HER2-positive breast cancer treated with dual HER2 blockade. *J Natl Cancer Inst.* April 2019. doi:10.1093/jnci/djz042.
2. Lesurf R, Griffith OL, Griffith M, et al. Genomic characterization of HER2-positive breast cancer and response to neoadjuvant trastuzumab and chemotherapy-results from the ACOSOG Z1041 (Alliance) trial. *Ann Oncol.* 2017;28(5):1070-1077. doi:10.1093/annonc/mdx048.
3. Ross DS, Zehir A, Cheng DT, et al. Next-Generation Assessment of Human Epidermal Growth Factor Receptor 2 (ERBB2) Amplification Status: Clinical Validation in the Context of a Hybrid Capture-Based, Comprehensive Solid Tumor Genomic Profiling Assay. *J Mol Diagn.* 2017;19(2):244-254. doi:10.1016/j.jmoldx.2016.09.010.
4. Vicario R, Peg V, Morancho B, et al. Patterns of HER2 Gene Amplification and Response to Anti-HER2 Therapies. *PLoS ONE.* 2015;10(6):e0129876. doi:10.1371/journal.pone.0129876.
5. Hiatt JB, Pritchard CC, Salipante SJ, O'Roak BJ, Shendure J. Single molecule molecular inversion probes for targeted, high-accuracy detection of low-frequency variation. *Genome Res.* 2013;23(5):843-854. doi:10.1101/gr.147686.112.

6. Christgen M, van Luttikhuizen JL, Raap M, et al. Precise ERBB2 copy number assessment in breast cancer by means of molecular inversion probe array analysis. *Oncotarget*. 2016;7(50):82733-82740. doi:10.18632/oncotarget.12421.
7. Christgen M, Harbeck N, Gluz O, Nitz U, Kreipe HH. Recognition and handling of discordant negative human epidermal growth factor receptor 2 classification by Oncotype DX in patients with breast cancer. *J Clin Oncol*. 2012;30(26):3313-4-authorreply3314-5. doi:10.1200/JCO.2012.42.1990.
8. Dabbs DJ, Klein ME, Mohsin SK, Tubbs RR, Shuai Y, Bhargava R. High false-negative rate of HER2 quantitative reverse transcription polymerase chain reaction of the Oncotype DX test: an independent quality assurance study. *J Clin Oncol*. 2011;29(32):4279-4285. doi:10.1200/JCO.2011.34.7963.
9. Denkert C, Loibl S, Kronenwett R, et al. RNA-based determination of ESR1 and HER2 expression and response to neoadjuvant chemotherapy. *Ann Oncol*. 2013;24(3):632-639. doi:10.1093/annonc/mds339.
10. Denkert C, Huober J, Loibl S, et al. HER2 and ESR1 mRNA expression levels and response to neoadjuvant trastuzumab plus chemotherapy in patients with primary breast cancer. *Breast Cancer Res*. 2013;15(1):R11. doi:10.1186/bcr3384.

## Zusatzuntersuchungen: Ki-67 Bestimmung

	Oxford		
	LoE	GR	AGO
▪ <b>Auszählung von Zellkernen an der Invasionsfront des Tumors</b>	5	D	++
▪ <b>Semiquantitative Schätzung oder Auszählen an Stanzbiopsaten</b>	2	A	++
▪ <b>Berücksichtigung auch schwach positiver Zellkerne</b>	5	D	++
▪ <b>Angabe des Ki-67 positiver Tumorzellen in Prozent</b>	5	D	++
▪ <b>Etablierung laborinterner Standards und Schwellenwerte</b>	5	D	++
▪ <b>Bildanalyse zur Objektivierung der Ki-67 Auszählung</b>	5	D	+
▪ <b>Neu-Bestimmung Ki-67 nach Kurzzeit präoperativer (2-4 Wochen) endokriner Induktion (ypTNM trotz Kurzzeit)*</b>	1b	B	+

\* Siehe Kapitel neoadjuvante Therapie

### Ki-67 Methods and Reproducibility

1. Leung SCY, Nielsen TO, Zabaglo L, et al. Analytical validation of a standardized scoring protocol for Ki67: phase 3 of an international multicenter collaboration. *npj Breast Cancer*. 2016;2:16014. doi:10.1038/npjbcancer.2016.14.
2. Gluz O, Nitz UA, Christgen M, et al. West German Study Group Phase III PlanB Trial: First Prospective Outcome Data for the 21-Gene Recurrence Score Assay and Concordance of Prognostic Markers by Central and Local Pathology Assessment. *J Clin Oncol*. 2016 Jul 10;34(20):2341-9. doi: 10.1200/JCO.2015.63.5383
3. Nielsen TO, Leung SCY, Rimm DL, Dodson A, Acs B, Badve S, Denkert C, Ellis MJ, Fineberg S, Flowers M, Kreipe HH, Laenkholm AV, Pan H, Penault-Llorca FM, Polley MY, Salgado R, Smith IE, Sugie T, Bartlett JMS, McShane LM, Dowsett M, Hayes DF. Assessment of Ki67 in Breast Cancer: Updated Recommendations From the International Ki67 in Breast Cancer Working Group. *J Natl Cancer Inst*. 2021 Jul 1;113(7):808-819. doi: 10.1093/jnci/djaa201

### Impact of Ki-67 staining

1. Tao M, Chen S, Zhang X, Zhou Q. Ki-67 labeling index is a predictive marker for a pathological complete response to neoadjuvant

chemotherapy in breast cancer: A meta-analysis. 2017;96(51):e9384. doi:10.1097/MD.0000000000009384

2. Ignatiadis M, Azim HA, Desmedt C, et al. The Genomic Grade Assay Compared With Ki67 to Determine Risk of Distant Breast Cancer Recurrence. *JAMA Oncol*. 2016;2(2):217-224. doi:10.1001/jamaoncol.2015.4377.
3. Nitz, U., Gluz, O., Huober, J., et al. (2014). Final analysis of the prospective WSG-AGO EC-Doc versus FEC phase III trial in intermediate-risk (pN1) early breast cancer: efficacy and predictive value of Ki67 expression. *Annals of Oncology : Official Journal of the European Society for Medical Oncology / ESMO*, 25(8), 1551–1557. doi:10.1093/annonc/mdu186
4. Inwald, E. C., Klinkhammer-Schalke, M., Hofstädter, F., et al. (2013). Ki-67 is a prognostic parameter in breast cancer patients: results of a large population-based cohort of a cancer registry. *Breast Cancer Research and Treatment*, 139(2), 539–552. doi:10.1007/s10549-013-2560-8
5. Penault-Llorca, F, F Andre, C Sagan, et al. “Ki67 Expression and Docetaxel Efficacy in Patients with Estrogen Receptor-Positive Breast Cancer.” *Journal of Clinical Oncology : Official Journal of the American Society of Clinical Oncology* 27, no. 17 (June 8, 2009): 2809–15. doi:10.1200/JCO.2008.18.2808.
6. Andre F, Ismaila N, Allison KH, Barlow WE, Collyar DE, Damodaran S, Henry NL, Jhaveri K, Kalinsky K, Kuderer NM, Litvak A, Mayer EL, Puzstai L, Raab R, Wolff AC, Stearns V. Biomarkers for Adjuvant Endocrine and Chemotherapy in Early-Stage Breast Cancer: ASCO Guideline Update. *J Clin Oncol*. 2022 Jun 1;40(16):1816-1837. doi: 10.1200/JCO.22.00069.

#### Ki-67 Image Analysis

1. Abubakar M, Orr N, Daley F, et al. Prognostic value of automated KI67 scoring in breast cancer: a centralised evaluation of 8088 patients from 10 study groups. *Breast Cancer Res*. 2016;18(1):104. doi:10.1186/s13058-016-0765-6.
2. Abubakar M, Howat WJ, Daley F, et al. High-throughput automated scoring of Ki67 in breast cancer tissue microarrays from the Breast Cancer Association Consortium. *J Pathol Clin Res*. 2016;2(3):138-153. doi:10.1002/cjp2.42.
3. Zhong F, Bi R, Yu B, Yang F, Yang W, Shui R. A Comparison of Visual Assessment and Automated Digital Image Analysis of Ki67 Labeling Index in Breast Cancer. *PLoS ONE*. 2016;11(2):e0150505. doi:10.1371/journal.pone.0150505.

4. Klauschen F, Wienert S, Schmitt WD, et al. Standardized Ki67 Diagnostics Using Automated Scoring--Clinical Validation in the GeparTrio Breast Cancer Study. *Clin Cancer Res*. 2015;21(16):3651-3657. doi:10.1158/1078-0432.CCR-14-1283.
5. Christgen M, Ahsen von S, Christgen H, Länger F, Kreipe H. The region-of-interest size impacts on Ki67 quantification by computer-assisted image analysis in breast cancer. *Hum Pathol*. 2015;46(9):1341-1349. doi:10.1016/j.humpath.2015.05.016.
6. Di Cataldo S, Ficarra E, Macii E. Computer-aided techniques for chromogenic immunohistochemistry: status and directions. *Comput Biol Med*. 2012;42(10):1012-1025. doi:10.1016/j.combiomed.2012.08.004.
7. Mohammed ZMA, McMillan DC, Elsberger B, et al. Comparison of visual and automated assessment of Ki-67 proliferative activity and their impact on outcome in primary operable invasive ductal breast cancer. *Br J Cancer*. 2012;106(2):383-388. doi:10.1038/bjc.2011.569.
8. Gudlaugsson, E., Skaland, I., Janssen, E. A. M., et al. (2012). Comparison of the effect of different techniques for measurement of Ki67 proliferation on reproducibility and prognosis prediction accuracy in breast cancer. *Histopathology*, 61(6), 1134–1144. doi:10.1111/j.1365-2559.2012.04329.x
9. Konsti J, Lundin M, Joensuu H, et al. Development and evaluation of a virtual microscopy application for automated assessment of Ki-67 expression in breast cancer. *BMC Clin Pathol*. 2011;11(1):3. doi:10.1186/1472-6890-11-3.

#### Ki67 als dynamischer Marker nach Kurzzeit endokriner Therapie


1. Dowsett M, Ellis MJ, Dixon JM, Gluz O et al. Evidence-based guidelines for managing patients with primary ER+ HER2- breast cancer deferred from surgery due to the COVID-19 pandemic. *NPJ Breast Cancer*. 2020 Jun 8;6:21.
2. Hofmann D, Nitz U, Gluz O, et al. WSG ADAPT - adjuvant dynamic marker-adjusted personalized therapy trial optimizing risk assessment and therapy response prediction in early breast cancer: Study protocol for a prospective, multi-center, controlled, non-blinded, randomized, investigator-initiated phase II/III trial. *Trials*. 2013;14:261-6215-14-261.
3. Smith IE, Robertson J, Kilburn L, et al. Long-term outcome and prognostic value of Ki67 after perioperative endocrine therapy in postmenopausal women with hormone sensitive early breast cancer:The POETIC randomised trial. *Lancet Oncology*. 2020.



## Prädiktive PD-L1 Bestimmung beim metastasierten, triple-negativen Mammakarzinom

Immunhistochemischer Nachweis	Oxford		
	LoE	GR	AGO
<b>Primärtumor- oder Metastasengewebe verwendbar</b>	2	A	++
<b>Primärantikörper äquivalent zu den Zulassungsstudien</b>	3	B	+
<b>CPS (combined positive score)</b> zur Indizierung von <b>Pembrolizumab</b> = Quotient: $\frac{\text{Positive Tumorzellen} + \text{Makrophagen} + \text{Lymphozyten}}{\text{Zahl der Tumorzellen} \times 100}$	2	A	++
<b>Schwellenwert CPS <math>\geq 10</math></b>	1b	A	
<b>Immun-Score (IC)</b> zur Indizierung von <b>Atezolizumab</b> : Zytoplasmatische Positivität des leukozytären Begleitinfiltrates (Lymphozyten, Makrophagen, Plasmazellen, Granulozyten außerhalb von Abszessen) bezogen auf die Tumorfläche	2	A	++
<b>Schwellenwert IC &gt; 1%</b>	1b	A	

- Schildhaus HU. Der prädiktive Wert der PD-L1-Diagnostik. *Der Pathologe*. 2018;39(6):498-519. doi:10.1007/s00292-018-0507-x.
- Cortes J, Rugo HS, Cescon DW, et al. KEYNOTE-355 Investigators. Pembrolizumab plus Chemotherapy in Advanced Triple-Negative Breast Cancer. *N Engl J Med*. 2022 Jul 21;387(3):217-226. doi: 10.1056/NEJMoa2202809.
- Schmid P, Cortes J, Dent R, et al. KEYNOTE-522 Investigators. Event-free Survival with Pembrolizumab in Early Triple-Negative Breast Cancer. *N Engl J Med*. 2022 Feb 10;386(6):556-567. doi: 10.1056/NEJMoa2112651
- Sharma P, Stecklein SR, Yoder R, et al. Clinical and Biomarker Findings of Neoadjuvant Pembrolizumab and Carboplatin Plus Docetaxel in Triple-Negative Breast Cancer: NeoPACT Phase 2 Clinical Trial. *JAMA Oncol*. 2023 Nov 22:e235033. doi: 0.1001/jamaoncol.2023.5033.
- Emens, L. A., Cruz, C., Eder, J. P., et al. (2018). Long-term Clinical Outcomes and Biomarker Analyses of Atezolizumab Therapy for Patients With Metastatic Triple-Negative Breast Cancer: A Phase 1 Study. *JAMA Oncology*. <http://doi.org/10.1001/jamaoncol.2018.4224>
- Schmid P, Adams S, Rugo HS, et al. Atezolizumab and Nab-Paclitaxel in Advanced Triple-Negative Breast Cancer. *N Engl J Med*. 2018;379(22):2108-2121. doi:10.1056/NEJMoa1809615.



## Mutationsdiagnostik\* bei mBC: „Precision medicine“ für zielgerichtete Therapien

Alteriertes Gen	Therapierelevanz	Genregion	Ausgangsmaterial	Oxford		AGO
				LOE	GR	
BRCA1, BRCA2	Olaparib, Talazoparib	Alle Exons	Keimbahn: Blutzellen	1b	A	++
	Olaparib		Somatisch: Gewebe	2b	B	+
PALB2	Olaparib		Keimbahn: Blutzellen	2b	B	+
PIK3CA	Alpelisib	Exon 7, 9 und 20	Primärtumor, Metastasen, Plasma	1b	A	++
AKT1, PTEN, PIK3CA	Capivasertib		Primärtumor, Metastasen, Plasma	1b	A	+
HER2-Mutation (unabh. vom HER2-Status)	Neratinib, Lapatinib	Kinase- und extrazelluläre Domänen; S310, L755, V777, Y772_A775dup	Primärtumor, Metastasen, Plasma; insbes. lobuläres CA	4	C	+/-
ESR1	Resistenz gegenüber AI Ansprechen Elacestrant	Exon 4, 7 und 8	Metastasen, Plasma	2b	B	+
			Metastasen, Plasma	1b	B	++
NTRK Genfusion	Larotrectinib, Entrectinib	Fusions- und Spleißvarianten	Tumor, bei sekretor. MammaCa	2a	B	+
MSI * idealerweise Paneldiagnostik	Pembrolizumab	Mikrosatelliten-Instabilität	Gewebe	2a	B	+

### BRCA 1/2:

1. Robson M, Im SA, Senkus E et al. (2017) Olaparib for Metastatic Breast Cancer in Patients with a Germline BRCA Mutation. *N Engl J Med.* 377:523-533. doi: 10.1056/NEJMoa1706450
2. Kaufman B, Shapira-Frommer R, Schmutzler RK et al. (2015) Olaparib monotherapy in patients with advanced cancer and a germline BRCA1/2 mutation. *J Clin Oncol.* 2015 Jan 20;33(3):244-50. doi: 10.1200/JCO.2014.56.2728.
3. Tung NM, Robson ME, Venz S, et al. TBCRC 048: Phase II Study of Olaparib for Metastatic Breast Cancer and Mutations in Homologous Recombination-Related Genes. *J Clin Oncol.* 2020 Dec 20;38(36):4274-4282.
4. Davies H, Glodzik D, Morganella S, et al. HRDetect is a predictor of BRCA1 and BRCA2 deficiency based on mutational signatures. *Nat Med.* 2017;83:1301. doi:10.1038/nm.4292.
5. Gross E, van Tinteren H, Li Z, et al. Identification of BRCA1-like triple-negative breast cancers by quantitative multiplex-ligation-dependent probe amplification (MLPA) analysis of BRCA1-associated chromosomal regions: a validation study. *BMC Cancer.* 2016;16(1):811. doi:10.1186/s12885-016-2848-2.
6. Telli ML, Timms KM, Reid J, et al. Homologous Recombination Deficiency (HRD) Score Predicts Response to Platinum-Containing Neoadjuvant Chemotherapy in Patients with Triple-Negative Breast Cancer. *Clin Cancer Res.* 2016;22(15):3764-3773. doi:10.1158/1078-0432.CCR-15-2477.

7. Petrillo M, Nero C, Amadio G, Gallo D, Fagotti A, Scambia G. Targeting the hallmarks of ovarian cancer: The big picture. *Gynecologic Oncology*. 2016;142(1):176-183. doi:10.1016/j.ygyno.2016.03.037.
8. Azzollini J, Scuvera G, Bruno E, et al. Mutation detection rates associated with specific selection criteria for BRCA1/2 testing in 1854 high-risk families: A monocentric Italian study. *Eur J Intern Med*. 2016;32:65-71. doi:10.1016/j.ejim.2016.03.010.
9. De Picciotto N, Cacheux W, Roth A, Chappuis PO, Labidi-Galy SI. Ovarian cancer: Status of homologous recombination pathway as a predictor of drug response. *Critical Reviews in Oncology/Hematology*. 2016;101:50-59. doi:10.1016/j.critrevonc.2016.02.014.
10. Lord CJ, Ashworth A. BRCAness revisited. *Nat Rev Cancer*. 2016;16(2):110-120. doi:10.1038/nrc.2015.21.

#### PIK3CA:

1. Andre F, Ciruelos E, Rubovszky G, Campone M et al. (2019) Alpelisib for PIK3CA-Mutated, Hormone Receptor-Positive Advanced Breast Cancer. *N Engl J Med*. 380:1929-1940. doi: 10.1056/NEJMoa1813904
2. Luen SJ, Asher R, Lee CK, et al. Association of Somatic Driver Alterations With Prognosis in Postmenopausal, Hormone Receptor-Positive, HER2-Negative Early Breast Cancer: A Secondary Analysis of the BIG 1-98 Randomized Clinical Trial. *JAMA Oncol*. 2018;4(10):1335-1343. doi:10.1001/jamaoncol.2018.1778.
3. Stearns V, Park BH. PIK3CA Mutations in Hormone Receptor-Positive Breast Cancers: PIKing Biomarkers to Inform Adjuvant Endocrine Therapy Decisions. *JAMA Oncol*. 2018;4(10):1330-1332. doi:10.1001/jamaoncol.2018.1766.
4. Lasota J, Felisiak-Golabek A, Wasąg B, et al. Frequency and clinicopathologic profile of PIK3CA mutant GISTs: molecular genetic study of 529 cases. *Mod Pathol*. 2016;29(3):275-282. doi:10.1038/modpathol.2015.160.
5. Wilson TR, Yu J, Lu X, et al. The molecular landscape of high-risk early breast cancer: comprehensive biomarker analysis of a phase III adjuvant population. *npj Breast Cancer*. 2016;2(1):16022. doi:10.1038/npjbcancer.2016.22.
6. Bosch A, Li Z, Bergamaschi A, et al. PI3K inhibition results in enhanced estrogen receptor function and dependence in hormone receptor-positive breast cancer. *Sci Transl Med*. 2015;7(283):283ra51-283ra51. doi:10.1126/scitranslmed.aaa4442.
7. Papaxoinis G, Kotoula V, Alexopoulou Z, et al. Significance of PIK3CA Mutations in Patients with Early Breast Cancer Treated with Adjuvant Chemotherapy: A Hellenic Cooperative Oncology Group (HeCOG) Study. *PLoS ONE*. 2015;10(10):e0140293. doi:10.1371/journal.pone.0140293.

8. Baselga J, Cortés J, Im S-A, et al. Biomarker analyses in CLEOPATRA: a phase III, placebo-controlled study of pertuzumab in human epidermal growth factor receptor 2-positive, first-line metastatic breast cancer. *J Clin Oncol*. 2014;32(33):3753-3761. doi:10.1200/JCO.2013.54.5384.
9. Henry NL, Schott AF, Hayes DF. Assessment of PIK3CA mutations in human epidermal growth factor receptor 2-positive breast cancer: clinical validity but not utility. *J Clin Oncol*. 2014;32(29):3207-3209. doi:10.1200/JCO.2014.57.6132.
10. André F, Bachelot T, Commo F, et al. Comparative genomic hybridisation array and DNA sequencing to direct treatment of metastatic breast cancer: a multicentre, prospective trial (SAFIR01/UNICANCER). *Lancet Oncol*. 2014;15(3):267-274. doi:10.1016/S1473-2045(13)70611-9.
11. Tandon M, Chen Z, Pratap J. Runx2 activates PI3K/Akt signaling via mTORC2 regulation in invasive breast cancer cells. *Breast Cancer Res*. 2014;16(1):R16. doi:10.1186/bcr3611.
12. Lehmann BD, Bauer JA, Schafer JM, et al. PIK3CA mutations in androgen receptor-positive triple negative breast cancer confer sensitivity to the combination of PI3K and androgen receptor inhibitors. *Breast Cancer Res*. 2014;16(4):406. doi:10.1186/s13058-014-0406-x.
13. Cizkova M, Dujaric M-E, Lehmann-Che J, et al. Outcome impact of PIK3CA mutations in HER2-positive breast cancer patients treated with trastuzumab. *Br J Cancer*. 2013;108(9):1807-1809. doi:10.1038/bjc.2013.164.
14. Vinayak S, Carlson RW. mTOR inhibitors in the treatment of breast cancer. *Oncology (Williston Park, NY)*. 2013;27(1):1-13
15. Campone M, Im SA, Iwata H, et al. Buparlisib plus fulvestrant versus placebo plus fulvestrant for postmenopausal, hormone receptor-positive, human epidermal growth factor receptor 2-negative, advanced breast cancer: Overall survival results from BELLE-2. *Eur J Cancer*. 2018 Nov;103:147-154.
16. Dickler MN, Saura C, Richards DA, et al. Phase II Study of Taselisib (GDC-0032) in Combination with Fulvestrant in Patients with HER2-Negative, Hormone Receptor-Positive Advanced Breast Cancer. *Clin Cancer Res*. 2018 Sep 15;24(18):4380-4387.

#### AKT1/PTEN:

1. Turner NC, Oliveira M, Howell S et al. (2022) Capivasertib and fulvestrant for patients with aromatase inhibitor-resistant hormone receptor-positive/human epidermal growth factor receptor 2-negative advanced breast cancer: results from the Phase III CAPitello-291 trial. *N Engl J Med* 388(22):2058–2070. doi:10.1056/NEJMoa221413123

- Hopcroft L, Wigmore EM, Williamson SC (2023) Combining the AKT inhibitor capivasertib and SERD fulvestrant is effective in palbociclib-resistant ER+ breast cancer preclinical models. *NPJ Breast Cancer* 9(1):64. doi:10.1038/s41523-023-00571-w

#### HER2-Mutation:

- Hyman DM, Piha-Paul SA, Won H, et al. (2018) HER kinase inhibition in patients with HER2- and HER3-mutant cancers. *Nature* 554:189-194. doi: 10.1038/nature25475.
- Ma CX, Bose R, Gao F, et al. (2017) Neratinib Efficacy and Circulating Tumor DNA Detection of HER2 Mutations in HER2 Nonamplified Metastatic Breast Cancer. *Clin Cancer Res.* 23:5687-5695. doi: 10.1158/1078-0432.CCR-17-0900.
- Hanker AB, Brewer MR, Sheehan JH, et al. An Acquired HER2(T798I) Gatekeeper Mutation Induces Resistance to Neratinib in a Patient with HER2 Mutant-Driven Breast Cancer. *Cancer Discov* 2017;7: 575-85.
- Xu X, De Angelis C, Burke KA, et al. HER2 Reactivation through Acquisition of the HER2 L755S Mutation as a Mechanism of Acquired Resistance to HER2-targeted Therapy in HER2(+) Breast Cancer. *Clin Cancer Res* 2017;23: 5123-34.
- Petrelli F, Tomasello G, Barni S, et al.: Clinical and pathological characterization of HER2 mutations in human breast cancer: a systematic review of the literature. *Breast Cancer Res Treat.* 2017;166(2):339-349. doi:10.1007/s10549-017-4419-x.
- Ross JS, Gay LM, Wang K, et al. Nonamplification ERBB2 genomic alterations in 5605 cases of recurrent and metastatic breast cancer: An emerging opportunity for anti-HER2 targeted therapies. *Cancer.* 2016;122(17):2654-2662. doi:10.1002/cncr.30102.
- Bose R, Kavuri SM, Searleman AC, et al. Activating HER2 mutations in HER2 gene amplification negative breast cancer. *Cancer Discov.* 2013;3(2):224-237. doi:10.1158/2159-8290.CD-12-0349.
- Weigelt B, Reis-Filho JS. Activating mutations in HER2: neu opportunities and neu challenges. *Cancer Discov.* 2013;3(2):145-147. doi:10.1158/2159-8290.CD-12-0585.
- Herter-Sprue GS, Greulich H, Wong K-K. Activating Mutations in ERBB2 and Their Impact on Diagnostics and Treatment. *Front Oncol.* 2013;3:86. doi:10.3389/fonc.2013.00086.
- Greulich H, Kaplan B, Mertins P, et al. Functional analysis of receptor tyrosine kinase mutations in lung cancer identifies oncogenic extracellular domain mutations of ERBB2. *Proc Natl Acad Sci U S A.* 2012;109(36):14476-14481. doi:10.1073/pnas.1203201109.
- Zito CI, Riches D, Kolmakova J, Simons J, Egholm M, Stern DF. Direct resequencing of the complete ERBB2 coding sequence reveals an absence of activating mutations in ERBB2 amplified breast cancer. *Genes Chromosomes Cancer.* 2008;47(7):633-638.

doi:10.1002/gcc.20566.

12. Lee JW, Soung YH, Seo SH, et al. Somatic mutations of ERBB2 kinase domain in gastric, colorectal, and breast carcinomas. *Clin Cancer Res.* 2006;12(1):57-61. doi:10.1158/1078-0432.CCR-05-0976.

#### ESR1:

1. Bidard FC, Kaklamani VG, Neven P, et al. (2022) Elacestrant (oral selective estrogen receptor degrader) Versus Standard Endocrine Therapy for Estrogen Receptor-Positive, Human Epidermal Growth Factor Receptor 2-Negative Advanced Breast Cancer: Results From the Randomized Phase III EMERALD Trial. *J Clin Oncol.* 2022 Oct 1;40(28):3246-3256. doi: 10.1200/JCO.22.00338. Epub 2022 May 18. PMID: 35584336; PMCID: PMC9553388.
2. Dustin D, Gu G, Fuqua SAW (2019) ESR1 mutations in breast cancer. *Cancer* 125:3714-3728 doi: 10.1002/cncr.32345.
3. Fribbens C, Garcia Murillas I, Beaney M et al. (2018) Tracking evolution of aromatase inhibitor resistance with circulating tumour DNA analysis in metastatic breast cancer. *Ann Oncol.*29:145-153. doi: 10.1093/annonc/mdx483
4. Fribbens C, O'Leary B, Kilburn L et al. (2016) Plasma ESR1 Mutations and the Treatment of Estrogen Receptor-Positive Advanced Breast Cancer. *J Clin Oncol.* 34:2961-8. doi: 10.1200/JCO.2016.67.3061
5. Bidard FC, Hardy-Bessard AC, Dalenc F, et al.; PADA-1 investigators.Switch to fulvestrant and palbociclib versus no switch in advanced breast cancer with rising ESR1 mutation during aromatase inhibitor and palbociclib therapy (PADA-1): a randomised, open-label, multicentre, phase 3 trial.*Lancet Oncol.* 2022 Nov;23(11):1367-1377.
6. Berger F, Marce M, Delaloge S, et al.; PADA-1 investigators Randomised, open-label, multicentric phase III trial to evaluate the safety and efficacy of palbociclib in combination with endocrine therapy, guided by ESR1 mutation monitoring in oestrogen receptor-positive, HER2-negative metastatic breast cancer patients: study design of PADA-1. *BMJ Open.* 2022 Mar 3;12(3):e055821.
7. Wong NZH, Yap DWT, Ong RJM, et al. Efficacy of Oral SERDs in the treatment of ER+, HER2 - metastatic breast cancer, a stratified analysis of the ESR1 wild type and mutant subgroups. *Ann Oncol.* 2023 Oct 21:S0923-7534(23)04328-4. doi: 10.1016/j.annonc.2023.10.122.
8. Grote I, Poppe A, Lehmann U, Christgen M, Kreipe H, Bartels S. Frequency of genetic alterations differs in advanced breast cancer between metastatic sites. *Genes Chromosomes Cancer.* 2024 Jan;63(1):e23199. doi: 10.1002/gcc.23199.
9. D, Gu G, Fuqua SAW. ESR1 mutations in breast cancer. *Cancer.* 2019;125(21):3714-3728. doi:10.1002/cncr.32345.

10. Jeselsohn R, Bergholz JS, Pun M, et al. Allele-Specific Chromatin Recruitment and Therapeutic Vulnerabilities of ESR1 Activating Mutations. *Cancer Cell*. 2018;33(2):173-186.e175. doi:10.1016/j.ccell.2018.01.004.
11. Bartels S, Christgen M, Luft A, et al. Estrogen receptor (ESR1) mutation in bone metastases from breast cancer. *Mod Pathol*. 2018;31(1):56-61. doi:10.1038/modpathol.2017.95.
12. Toy W, Weir H, Razavi P, et al. Activating ESR1 Mutations Differentially Affect the Efficacy of ER Antagonists. *Cancer Discov*. 2017;7(3):277-287. doi:10.1158/2159-8290.CD-15-1523.
13. Chandarlapaty S, Chen D, He W, et al. Prevalence of ESR1 Mutations in Cell-Free DNA and Outcomes in Metastatic Breast Cancer: A Secondary Analysis of the BOLERO-2 Clinical Trial. *JAMA Oncol*. 2016;2(10):1310-1315. doi:10.1001/jamaoncol.2016.1279.
14. Jeselsohn R, Yelensky R, Buchwalter G, et al. Emergence of constitutively active estrogen receptor- $\alpha$  mutations in pretreated advanced estrogen receptor-positive breast cancer. *Clin Cancer Res*. 2014;20(7):1757-1767. doi:10.1158/1078-0432.CCR-13-2332.
15. Segal CV, Dowsett M. Estrogen receptor mutations in breast cancer--new focus on an old target. *Clin Cancer Res*. 2014;20(7):1724-1726. doi:10.1158/1078-0432.CCR-14-0067.
16. Giguère V. Estrogen receptor mutations in breast cancer-an anticipated "rediscovery?". *Mol Endocrinol*. 2014;28(4):427-428. doi:10.1210/me.2014-1071.
17. Fuqua SAW, Gu G, Rechoum Y. Estrogen receptor (ER)  $\alpha$  mutations in breast cancer: hidden in plain sight. *Breast Cancer Res Treat*. 2014;144(1):11-19. doi:10.1007/s10549-014-2847-4.

#### NTRK:

1. Maund SL, Sokol ES, Ang Houle A, et al. NTRK gene fusions are detected in both secretory and non-secretory breastcancers. *Pathol Int*. 2022 Mar;72(3):187-192.
2. Stenzinger A, van Tilburg CM, Tabatabai G, et al. [Diagnosis and therapy of tumors with NTRK gene fusion]. *Pathologe*. 2021 Feb;42(1):103-115.
3. Remoue A, Conan-Charlet V, Bourhis A, et al. Non-secretory breast carcinomas lack NTRK rearrangements and TRK protein expression. *Pathol Int*. 2019;69(2):94-96. doi:10.1111/pin.12766.

4. Ricciuti B, Genova C, Crinò L, Libra M, Leonardi GC. Antitumor activity of larotrectinib in tumors harboring NTRK gene fusions: a short review on the current evidence. *Onco Targets Ther.* 2019;12:3171-3179. doi:10.2147/OTT.S177051.
5. Condorelli R, Mosele F, Verret B, et al. Genomic alterations in breast cancer: level of evidence for actionability according to ESMO Scale for Clinical Actionability of molecular Targets (ESCAT). *Ann Oncol.* 2019;30(3):365-373. doi:10.1093/annonc/mdz036.
6. Cocco E, Scaltriti M, Drilon A. NTRK fusion-positive cancers and TRK inhibitor therapy. *Nat Rev Clin Oncol.* 2018;15(12):731-747. doi:10.1038/s41571-018-0113-0.
7. Pfarr N, Kirchner M, Lehmann U, et al. Testing NTRK testing: Wet-lab and in silico comparison of RNA-based targeted sequencing assays. *Genes Chromosomes Cancer.* 2020;59(3):178-188. doi:10.1002/gcc.22819.

#### MSI:

1. FDA approval across tumor entities (23.5.17): see full prescribing information for pembrolizumab

#### PALB2:

1. Antoniou AC, Casadei S, Heikkinen T et al. Breast Cancer Risk in families with mutations in PALB2. *N Engl J Med* 2014;371(6):497-506.
  2. Breast Cancer Association Consortium, Dolling L, Carvahlo S, Allen J et al. Breast Cancer Risk Genes - Association Analysis in more than 113,000 women. *N Engl J Med* 2021;384(5):428-439.
  3. Couch FJ, Shimelis H, Hu C et al. Associations between cancer predisposition testing panel genes and breast cancer. *JAMA Oncol* 2017;3(9):1190-1196.
  4. Tung NM, Robson ME, Ventz S, TBCRC 048: Phase II Study of Olaparib for Metastatic Breast Cancer and Mutations in Homologous Recombination-Related Genes. *J Clin Oncol.* 2020 Dec 20;38(36):4274-4282.
- 
1. Cortes-Ciriano I, Lee S, Park W-Y, Kim TM, Park PJ. A molecular portrait of microsatellite instability across multiple cancers. *Nature Communications.* 2017;8:15180. doi:10.1038/ncomms15180.
  2. Win AK, Lindor NM, Jenkins MA. Risk of breast cancer in Lynch syndrome: a systematic review. *Breast Cancer Res.* 2013;15(2):R27.



doi:10.1186/bcr3405.

3. Engel C, Loeffler M, Steinke V, et al. Risks of less common cancers in proven mutation carriers with lynch syndrome. *J Clin Oncol.* 2012;30(35):4409-4415. doi:10.1200/JCO.2012.43.2278.