

Diagnosis and Treatment of Patients with early and advanced Breast Cancer



© AGO e. V.
in der DGGG e.V.
sowie
in der DKG e.V.

Guidelines Breast
Version 2022.2E

Pathology

www.ago-online.de

FORSCHEN
LEHREN
HEILEN

Pathology

© AGO e. V.
in der DGGG e.V.
sowie
in der DKG e.V.

Guidelines Breast
Version 2022.2E

- **Versions 2004–2021:**
Blohmer / Costa / Fehm / Friedrichs / Harbeck / Huober / Kreipe / Lück / Maass / Schmidt / Schneeweiss/ Sinn / Thomssen
- **Version 2022:**
Sinn / Huober / Kreipe

Preamalytics: Fixation

© AGO e. V.
in der DGGG e.V.
sowie
in der DKG e.V.

Guidelines Breast
Version 2022.2E

- **Minimize time to fixation (cold ischemia time)**
- **Minimal fixation time of 6 hours for optimal antigen preservation**
- **Optimal fixation time 6 - 72 h for core biopsies**
- **Optimal fixation time for resection specimens: 12 - 72 h**
- **Use of neutral buffered formalin**

	Oxford		
	LoE	GR	AGO
Minimize time to fixation (cold ischemia time)	5	D	++
Minimal fixation time of 6 hours for optimal antigen preservation	5	D	++
Optimal fixation time 6 - 72 h for core biopsies	5	D	++
Optimal fixation time for resection specimens: 12 - 72 h	5	D	++
Use of neutral buffered formalin	5	D	++

Use of Breast Cytology*

© AGO e. V.
in der DGGG e.V.
sowie
in der DKG e.V.

Guidelines Breast
Version 2022.2E

- Nipple secretion
- Tumor*
- Cyst
- Lymph node

Oxford		
LoE	GR	AGO
5	D	+
5	D	-
5	D	+/-
5	D	+/-

* Ultrasound-guided core biopsy recommended

Workup: Core Needle Biopsies (US-Guided or Stereotactic)

© AGO e. V.
in der DGGG e.V.
sowie
in der DKG e.V.

Guidelines Breast
Version 2022.2E

- **Routine workup in step sections
(14G: 1–3 step sections / 11G, 8G: 6–8 step sections)**
- **Correlation with imaging (density, calcifications),
use of B-classification**
- **Frozen section diagnosis on core biopsies**
- **Routine evaluation of ER / PR and HER2 status**
- **Turn-around time < 24 h (histology)**

	Oxford		
	LoE	GR	AGO
	5	D	++
	1b	B	++
	5	D	--
	3b	C	++
	5	D	+

Workup: Breast-Conserving Specimens

© AGO e. V.
in der DGGG e.V.
sowie
in der DKG e.V.

Guidelines Breast
Version 2022.2E

- **Slicing perpendicular to the longitudinal axis (or perpendicular to the nipple-peripheral axis in case of spherical specimens)**
- **Systematic sampling, at least 1 tissue block every 1 cm**
- **Inking of resection margins. Sampling of resection margins**
- **Documentation after slicing using specimen radiography, photo documentation or diagram**

	Oxford		
	LoE	GR	AGO
	5	D	++
	5	D	++
	5	D	++
	5	D	+

Workup: Mastectomy Specimens

© AGO e. V.
in der DGGG e.V.
sowie
in der DKG e.V.

Guidelines Breast
Version 2022.2E

	Oxford		
	LoE	GR	AGO
<ul style="list-style-type: none"> ■ Margins always to be sampled <ul style="list-style-type: none"> ■ Skin close to tumor ■ Deep margin ■ Other margins, if close (< 1 cm) 	5	D	++
<ul style="list-style-type: none"> ■ Attention to soft tissue margins in skin sparing mastectomy 	5	D	++
<ul style="list-style-type: none"> ■ Routine sampling of uninvolved quadrants, skin above tumor and retroareolar region 	5	D	++
<ul style="list-style-type: none"> ■ Systematic sampling in prophylactic mastectomies (patients with BRCA-1/2 mutation) 	5	D	++

Workup: Sentinel Node Biopsy

	Oxford		
	LoE	GR	AGO
■ Full workup using step sections of $\leq 500 \mu\text{m}$ on paraffin embedded tissue	5	D	++
■ Cytokeratin immunohistochemistry			
■ If suspicious, to detect micrometastases	2b	B	+
■ For micrometastasis detection after NACT	2b	B	+
■ As a routine procedure	5	D	+/-
■ Frozen section (compromises paraffin histomorphology)			
■ If clinical consequences	5	D	+
■ If no clinical consequences from frozen section (e.g. cT1 or cT2 and cN0 and BCT)	5	D	-
■ Imprint cytology instead of, or in addition to frozen section	3b	C	+/-
■ RT-PCR for epithelial genes	4	D	-
■ OSNA	3b	B	-

© AGO e. V.
in der DGGG e.V.
sowie
in der DKG e.V.

Guidelines Breast
Version 2022.2E

Workup: Intraoperative Pathological Evaluation and Frozen Sections



© AGO e. V.
in der DGGG e.V.
sowie
in der DKG e.V.

Guidelines Breast
Version 2022.2E

www.ago-online.de

FORSCHEN
LEHREN
HEILEN

	Oxford		
	LoE	GR	AGO
<ul style="list-style-type: none"> ▪ Sentinel node biopsy for invasive cancer (compromises final paraffin histomorphology) <ul style="list-style-type: none"> ▪ If clinical consequences ▪ No clinical consequences ▪ Closest margin of resection <ul style="list-style-type: none"> ▪ If macroscopically < 1 cm ▪ If macroscopically > 1 cm ▪ Lesions ≥ 1 cm, without core biopsy ▪ Non-palpable lesions or lesions < 1 cm ▪ Conservation of fresh tissue (tumor banking) 	5	D	+
	5	D	-
	5	D	+
	5	D	-
	5	D	+
	5	D	--
	5	D	+

Reporting: Histologic Tumor Type

Oxford		
LoE	GR	AGO
3b	C	++

- **Histologic tumor typing according to WHO-Classification, (5th ed., 2019)**
 - **Partial special differentiation:**
 > 50 % NST component
 and < 50 % special tumor type (minor component)
 - **Mixed differentiation:**
 > 50 % special tumor type
 and < 50 % NST component
 Example: mucinous breast cancer, mixed type
 - **Pure types:**
 > 90 % special tumor type
 Examples: tubular or cribriform Ca.

Ductal TNBC: Comparable Survival Rates and Similar Response Rates to Chemotherapy for ER = 0 % Compared to ER 1 % - < 10 %

Reference	Patients	Results
Villegas, S. L. <i>Eur J Cancer</i> 148 , 159–170 (2021) DOI: 10.1016/j.ejca.2021.02.020	Neoadjuvant clinical trial cohorts (n = 2765) comparing neg. ER/PR (< 1%) vs. ER/PR low pos. (ER and/or PR < 9%) vs. strong-pos. (ER or PR >= 10%) HR expression.	Low HR-positive, HER2-negative tumours had a similar clinical behavior compared to TNBC, showing high pCR rates and poor survival and also a basal-like gene expression signature. Patients with low HR-positive tumours should be regarded as candidates for therapy strategies targeting TNBC.
Dieci, M. V. et al. <i>Npj Breast Cancer</i> 7, 101 (2021) DOI: 10.1038/s41523-021-00308-7	406 patients with ER < 10% HER2-negative BC. Pat. Were categorized in ER-negative (ER < 1%; N = 364) and ER-low positive (1–9%, N = 42).	No difference was observed in overall survival (OS) according to ER expression levels (5-years OAS 82.3% vs. 76.7% for ER-negative and ER-low positive BC, respectively, p = 0.8). Our results suggest the use of a 10% cut-off, rather than <1%, to define triple-negative BC (TNBC).
Reddy, S. M. <i>et al.</i> <i>British Journal of Cancer</i> 118 , 17–23 (2018) DOI: 10.1038/bjc.2017.379	Stage I-III TNBC pat. (n = 873) who were disease free at 5 years from diagnosis. Recurrence-free interval (RFI), r.f. survival (RFS), and distant r.f. survival (DRFS) rates were calculated.	After a disease-free interval of 5 years, patients with low hormone receptor-pos. cancers had a higher risk of late events as measured by RFS, and similar risk by RFI or DRFS, compared to TNBC survivors.

Rare Histological TNBC Subtypes Show Divergent Tumor Differentiation Patterns and Clinical Behavior



© AGO e. V.
in der DGGG e.V.
sowie
in der DKG e.V.

Guidelines Breast
Version 2022.2E

Apocrine TNBC

- Luminal phenotype (no basal markers)
- High expression of the androgen receptor
- Low tumor proliferation
- Poor response to chemotherapy
- Better prognosis than ductal TNBC

Metaplastic TNBC

- See chapter 15 Special Situations

Rare and salivary-type TNBC

- Tumors with divergent clinical behavior and specific genetic alterations
- Mostly low tumor proliferation
- Poor response to conventional chemotherapy
- Experimental treatment according to the molecular pathology (e.g. NTREK for secretory ca.)

www.ago-online.de

FORSCHEN
LEHREN
HEILEN

Apocrine TNBC: More Favorable Survival and Poor Response to Adjuvant Chemotherapy

Reference	Patients	Results
<p>Saridakis, A. <i>et al.</i> <i>Ann Surg Oncol</i> 28, 5610–5616 (2021). DOI: 10.1245/s10434-021-10518-9</p>	<p>Women with invasive apocrine cancer were retrospectively identified from the Surveillance, Epidemiology, and End Results (SEER) database. N = 533 triple-negative apocrine cancers were identified.</p>	<p>Half of apocrine tumors are triple negative, but these have more favorable features and much better survival than non-apocrine triple-negative cancers. Compared with non-apocrine triple-negative, apocrine triple-negative patients were much older, with smaller, lower-grade tumors and much better survival (86% vs. 74%).</p>
<p>Montagna, E. <i>et al.</i> <i>Breast</i> 53, 138–142 (2020). DOI: 10.1038/s41523-021-00308-7</p>	<p>406 patients with ER < 10% HER2-negative BC. Pat. Were categorized in ER-negative (ER < 1%; N = 364) and ER-low positive (1–9%, N = 42).</p>	<p>The outcome of selected apocrine triple negative breast cancer patients who did not received adjuvant chemotherapy is excellent and supports a treatment de-escalation.</p>
<p>Mills, A. M., <i>et al.</i> <i>Am J Surg Pathol</i> 40, 1109–1116 (2016). DOI: 10.1097/pas.0000000000000671</p>	<p>All pure apocrine carcinomas diagnosed during a 10-year period were reviewed, and clinicopathologic characteristics were compared with a control group of 26 non-apocrine TNBC cases. Twenty apocrine carcinomas were identified (~ 0.8% of all breast cancers).</p>	<p>Apocrine TNBC had a favorable clinical prognosis, with 80% of patients showing no evidence of disease-related morbidity or mortality (mean follow-up: 45.2 mo). Pure apocrine carcinomas represent a clinicopathologically distinct subgroup of triple-negative breast cancer characterized by AR positivity.</p>

© AGO e. V.
in der DGGG e.V.
sowie
in der DKG e.V.

Guidelines Breast
Version 2022.2E

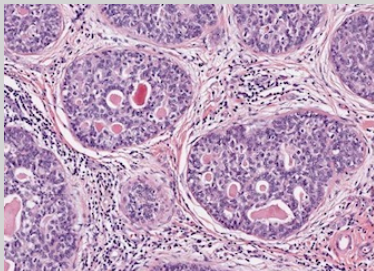
www.ago-online.de

Rare and Salivary-Type TNBC: Tumors with Divergent Clinical Behavior and Specific Genetic Alterations

© AGO e. V.
in der DGGG e.V.
sowie
in der DKG e.V.

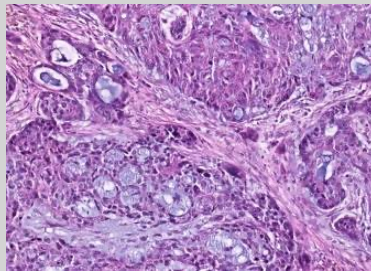
Guidelines Breast
Version 2022.2E

Adenoid-cystic carcinoma



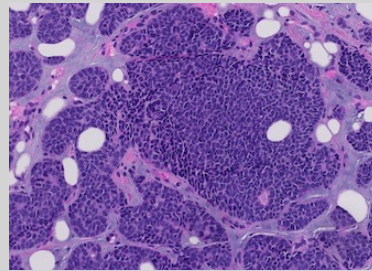
MYB-NFIB
MYBL1 rearrangements
MYB gene amplification

Secretory carcinoma



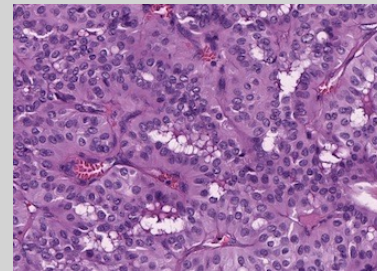
ETV6-NTRK3
gene fusions

Polymorphous carcinoma



PRKD1 E710D
PRKD1 / PRKOZ / PRKD3
rearrangements

Tall cell carcinoma with reversed polarity



IDH2 hotspot mutations

Reporting: Grade of Malignancy

Oxford		
LoE	GR	AGO
5	D	++
5	D	++
5	D	++
5	D	++

- **Use of Nottingham grading system (Elston & Ellis 1991) for all types of invasive breast cancer (incl. status post neoadjuvant systemic therapy)**
- **In case of very little tumor tissue, pure nuclear grading or additional criteria, such as Ki-67 proliferation fraction, may be used**
- **Grading of DCIS, e.g. according to WHO-Classification, (5th ed., 2019)**
- **Reporting of tumor grade in numeric form (e.g. G3)**

© AGO e. V.
in der DGGG e.V.
sowie
in der DKG e.V.

Guidelines Breast
Version 2022.2E

Reporting: Tumor Size and Total Extent of Tumor

Oxford		
LoE	GR	AGO
5	D	++
5	D	++
5	D	++

- Reporting of invasive tumor size taking into account macroscopic and histologic findings and clinical imaging results
- Additional reporting of total extent of invasive carcinoma in case of satellite nodules or multifocality
- Reporting of size of non-invasive component (DCIS or LCIS) when DCIS or LCIS component is extensive (more than 2 x invasive Ca)

Reporting: pTNM

Oxford		
LoE	GR	AGO
5	D	++

- Use of current UICC classification (8th ed.)

pT 1-3: Invasive tumor size (largest focus in case of multifocality or multicentricity)

pT4: Invasion of dermis alone does not qualify as pT4. Criteria for pT4a/b/c/d must be met.

pT4d: Negative skin biopsy does not rule out pT4d (inflammatory carcinoma).

pM: pM1 indicates any non-regional disease, except 2nd primary contralateral.
Use of MX is not recommended.

Reporting: Margins of Resection and R-Classification



© AGO e. V.
in der DGGG e.V.
sowie
in der DKG e.V.

Guidelines Breast
Version 2022.2E

- Evaluation of distance to all resection margins macroscopically and close margins histologically (< 1 cm)
- Reporting of minimal distance to resection margin and its topography
- R-Classification

R0: No residual tumor

R1: Microscopic invasive or noninvasive carcinoma involving resection margin

RX: Presence of residual tumor cannot be assessed (e.g. tumor in multiple specimens)

Oxford		
LoE	GR	AGO
5	D	++
5	D	++
5	D	++

Reporting: Lymphovascular Invasion

© AGO e. V.
in der DGGG e.V.
sowie
in der DKG e.V.

Guidelines Breast
Version 2022.2E

- **L1: Lymphovascular invasion**
L0: No lymphovascular invasion
- **IHC for evaluation of lymphovascular invasion**
- **Differentiation of peritumoral and extensive lymphovascular invasion**
- **Reporting of venous invasion (V0/V1) optional, prognostic significance not established**

Oxford		
LoE	GR	AGO
5	D	++
3b	C	-
3b	C	++
5	D	+

Reporting: Evaluation of Tumor-Infiltrating Lymphocytes (TIL)

Oxford		
LoE	GR	AGO
5	D	+/-

- **Identification of tumors with predominant lymphocytic infiltrate (> 50 %) in tumor stroma (according to Salgado et al.*)**

Consider only lymphocytic infiltrate in tumor stroma and not at the invasion front

Do not consider central fibrosis and necrotic areas

Report average of lymphocytic infiltrate as percentage

* Salgado, R., Denkert, C., Demaria, S., Sirtaine, N., Klauschen, F., Pruneri, G., et al. (2014). The evaluation of tumor-infiltrating lymphocytes (TILs) in breast cancer: recommendations by an International TILs Working Group 2014. *Annals of Oncology*

Reporting: Evaluation after Neoadjuvant Chemotherapy

Oxford

	LoE	GR	AGO
▪ Identification of tumor bed, otherwise ypTX	4	D	++
▪ Reporting of tumor size as total extent of tumor bed area involved by infiltrates of residual vital invasive carcinoma	4	D	++
▪ pCR when absence of invasive Ca. and absence of angioinvasion or LN metastases. Presence of ypTis should be recorded	2b	D	+
▪ Use of IHC to identify tumor residues (lymphnodes)	2b	B	+/-
▪ Reporting of ypTN after neoadjuvant systemic therapy	5	D	++
▪ Repeat IHC for ER, PR, and HER2	5	D	+/-
▪ Intraoperative frozen section (reduced sensitivity)	5	D	-
▪ Tumorregression-Scores: RCB-Score or Sataloff-Score	4	D	+/-

Special Studies: ER-Testing by IHC

© AGO e. V.
in der DGGG e.V.
sowie
in der DKG e.V.

Guidelines Breast
Version 2022.2E

- Immunohistochemical detection on paraffin embedded (FFPE) tissue
- Reporting percentage of pos. tumor nuclei (pos. if $\geq 10\%$, low pos. if $\geq 1\%$ – 10%)
- Staining intensity
- Only Allred Score (0–8) or Remmele Score (0–12)
- Re-evaluation on excision specimen if uncertain or triple-negative on core biopsy

Oxford		
LoE	GR	AGO
1a	A	++
1a	A	++
4	D	+
4	D	-
5	D	+

Low ER+ (1–10 %)

© AGO e. V.
in der DGGG e.V.
sowie
in der DKG e.V.

Guidelines Breast
Version 2022.2E

Reference	Patients	Results
Sanford, R. A. <i>et al.</i> <i>Cancer</i> 121 , 3422–3427 (2015). DOI: 10.1002/cncr.29572	314 Pat. 1–9% ER, Anteil BRCA mutierter Fälle wie bei ER -	High Incidence of Germline BRCA Mutation in Patients with ER Low-Positive / PR Low-Positive / HER-2 neu Negative Tumors
Deyarmin, B. <i>et al.</i> <i>Ann Surg Oncol</i> 20 , 87–93 (2013). DOI: 10.1245/s10434-012-2588-8	26 Pat. 1–10% ER, Genexpression eher wie TN oder HER2 enr	Effect of ASCO / CAP Guidelines for Determining ER Status on Molecular Subtype
Prabhu, J. S. <i>et al.</i> <i>J Cancer</i> 5 , 156–165 (2014) DOI: 10.7150/jca.7668	21 Pat. 1–10% ER, Genexpression wie ER-, Überleben < ER+	A Majority of Low (1–10%) ER Positive Breast Cancers Behave Like Hormone Receptor Negative Tumors
Yi, M. <i>et al.</i> <i>Annals of Oncology</i> 25 , 1004–1011 (2014). DOI: 10.1093/annonc/mdu053	251 Pat. 1–9% ER Überleben = ER-	Which threshold for ER positivity? A retrospective study based on 9639 patients

Special Studies: PR-Testing by IHC

© AGO e. V.
in der DGGG e.V.
sowie
in der DKG e.V.

Guidelines Breast
Version 2022.2E

- Immunohistochemical detection on paraffin embedded (FFPE) tissue
- Reporting percentage of pos. tumor nuclei (pos. if $\geq 10\%$)
- Only Allred Score (0 - 8) or Remmele Score (0 - 12)

Oxford		
LoE	GR	AGO
1a	A	++
1a	A	++
4	D	-

Additional Special Studies: Molecular Analysis of ER / PR Status

© AGO e. V.
in der DGGG e.V.
sowie
in der DKG e.V.

Guidelines Breast
Version 2022.2E

- Evaluation of hormone receptors using validated gene expression test kits
- Exclusive evaluation of hormone receptor by RNA-quantification
- Use of molecular receptor analysis for subtyping

	Oxford		
	LoE	GR	AGO
	3b	A	+/-
	5	D	-
	3b	A	+/-

HER2-Analysis by IHC

Oxford

LoE	GR	AGO
-----	----	-----

1a	A	++
----	---	----

- **Reporting of immunohistochemistry (IHC):**
 - **3+ staining pattern: HER2+ if strong complete circular membrane staining of > 10 % invasive cells**
 - **2+ staining pattern: If > 10 % circular but moderate / weak membrane staining or ≤ 10 % strong staining, U-shaped staining in micropapillary carcinoma: ISH required (CISH, SISH, FISH)**
 - **1+ staining pattern: with >10 % incomplete membrane staining that is weak or barely perceptible (caveat: reproducibility).**
 - **HER2-low: 1+ or 2+/ISH negative**

1a	A	++
----	---	----

1a	A	+
----	---	---

?	?	++
---	---	----

HER2-Analysis by ISH when IHC 2+

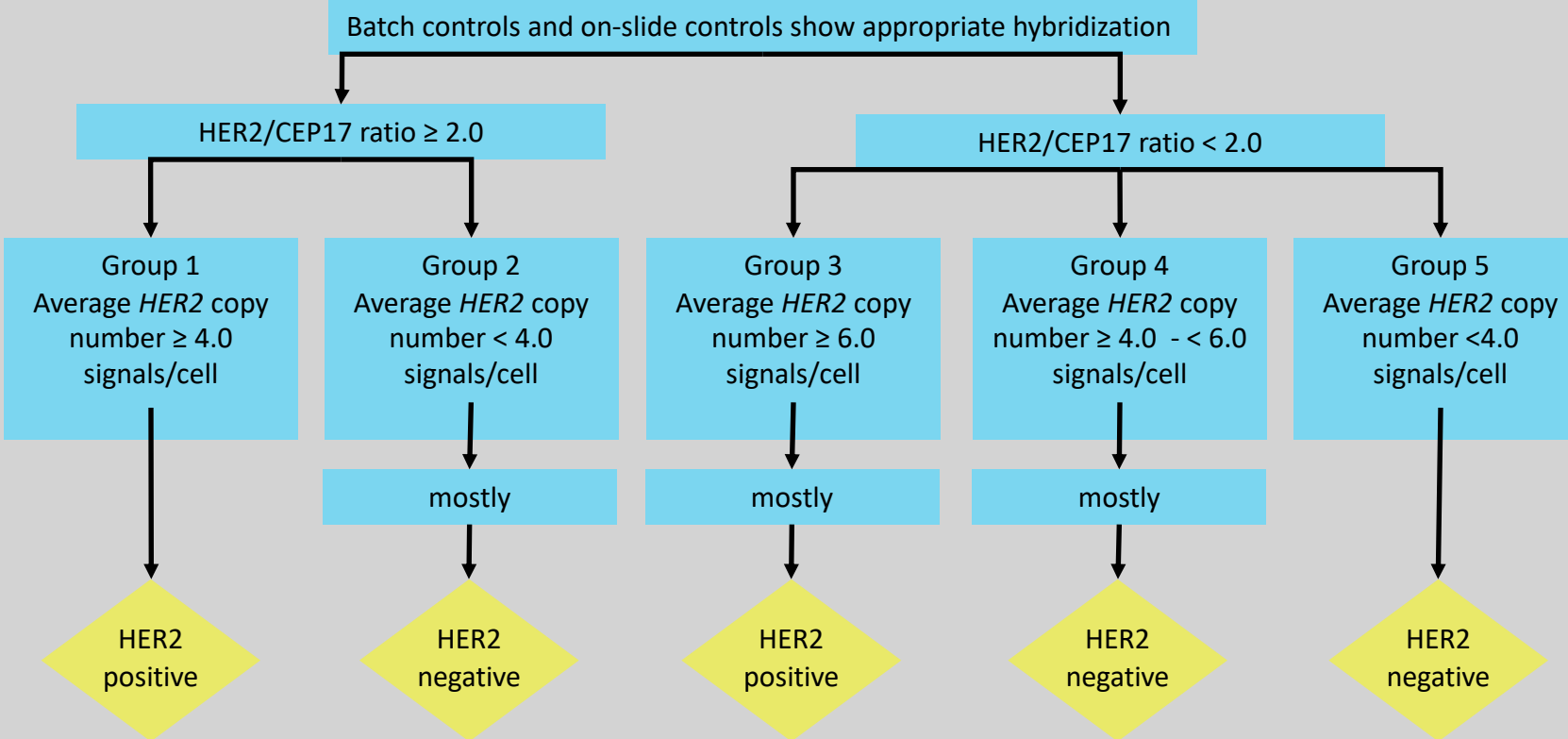
Oxford		
LoE	GR	AGO
3a	C	++
3a	D	++

- **Single-Color In-Situ-Hybridisation (ISH):**
 - HER2+ if signal counts ≥ 6 in at least 20 cohesive cells
 - negative if signal counts < 4 signals/nucleus
 - 2-Color ISH recommended for ≥ 4 and < 6 signals/nucleus
- **Two-Color In-Situ-Hybridisation (ISH):**
 - Group 1: Ratio ≥ 2.0 and signals/nucleus $\geq 4.0 \rightarrow$ HER2+
 - Group 2: Ratio ≥ 2.0 and signals/nucleus $< 4.0 \rightarrow$ HER2- (no benefit of anti-HER2 therapy)
 - Group 3: Ratio < 2.0 and signals/nucleus $\geq 6.0 \rightarrow$ HER2+ (but benefit of anti-HER2 therapy not certain)
 - Group 4: Ratio < 2.0 and signals/nucleus ≥ 4.0 und $< 6 \rightarrow$ HER2- (no benefit of anti-HER2 therapy)
 - Group 5: Ratio < 2.0 und signals/nucleus $< 4.0 \rightarrow$ HER2-

HER2 Testing by Validated Dual-Probe ISH Assay when IHC = 2+

© AGO e. V.
in der DGGG e.V.
sowie
in der DKG e.V.

Guidelines Breast
Version 2022.2E



HER2 Testing on Core Biopsies

© AGO e. V.
in der DGGG e.V.
sowie
in der DKG e.V.

Guidelines Breast
Version 2022.2E

False positive immunohistochemical labeling may occur in core biopsies. Therefore, methods of individual laboratories should be validated by comparison of core biopsies and resection specimens. Background staining should be evaluated by comparison with normal duct epithelium.

Alternatively, all G1 and G2 cases with HER2 3+ in core biopsies may be analyzed by ISH or may be re-evaluated in the resection specimen.

False positivity is likely when HER+ was reported in G1 tumors of the following types: Infiltrating ductal or lobular carcinoma, ER and PR positive, Tubular (at least 90 % pure), Mucinous (at least 90 % pure) Cribriform (at least 90 % pure), Adenoid cystic carcinoma (90 % pure).

In case of discrepancy between core biopsy and specimen, the HER2 overexpressing sample should be re-evaluated by a different method. If still discrepancy – anti-HER2-treatment if amplified in one of both samples. Expected rate of HER2-overexpression: 15 % HER2 positive.

Additional Special Studies: Molecular Analysis of HER2 Status

© AGO e. V.
in der DGGG e.V.
sowie
in der DKG e.V.

Guidelines Breast
Version 2022.2E

- Therapy decisions should only be based on IHC and ISH
- Evaluation of HER2 using validated gene expression test kits
- Evaluation of HER2-amplification by RNA-sequencing
- Use of molecular HER2-testing for subtyping

	Oxford		
	LoE	GR	AGO
	1a	A	++
	3b	B	-
	5	D	-
	3b	B	+/-

Special Studies: Evaluation of Ki-67 Score

© AGO e. V.
in der DGGG e.V.
sowie
in der DKG e.V.

Guidelines Breast
Version 2022.2E

	Oxford		
	LoE	GR	AGO
▪ Counting of tumor nuclei at the invasion front	5	D	++
▪ Semiquantitative eyeballing or counting of labelled cells in core needle biopsies	2	A	++
▪ Consideration of weakly stained tumor nuclei	5	D	++
▪ Reporting of Ki-67 positive nuclei as percentage	5	D	++
▪ Establishing of laboratory standards and cut-off values	5	D	++
▪ Use of image analysis for objective Ki-67 evaluation	5	D	+
▪ Determination of Ki-67 dynamics after short term (2-4 weeks) endocrine therapy*	1b	B	+



Reproducibility – Quality Assurance is Key for Clinical Decision Making

© AGO e. V.
in der DGGG e.V.
sowie
in der DKG e.V.

Guidelines Breast
Version 2022.2E

- **ER / PR: concordance central vs local is high (97 %; Plan B, SABCS 2014)**
- **Grade: concordance central vs local is 68 % (PlanB, JCO 2016)**
- **HER2: frequency of false-positive test results 6 % (ASCO /CAP JCO 2013)**
- **Impact of routine pathologic review in N0 BC: 20 % changes: grade 40 %, LVI 26 %, N 15 %, margin 12 % (JCO 2012)**
- **pN0 from MIRROR study: pN0 was upstaged in 22 %, in central pathology review (Ann Oncol 2012)**
- **Ki-67:**
 - **Inter- and intraobserver variability in measurement of Ki-67 is high (J Nat. Cancer Institute 2011)**
 - **High reproducibility for low and high Ki-67 levels (J Pathol 2002)**
 - **Standardized methodology improves analytical validity (JNCI 2020)**

www.ago-online.de

**FORSCHEN
LEHREN
HEILEN**

Predictive PD-L1 Assay

Oxford

LoE	GR	AGO
-----	----	-----

2	A	++
---	---	----

Immunohistochemical assay

Immune Score (IC): Cytoplasmic staining of at least 1 % of the leucocyte stromal infiltrate (lymphocytes, macrophages, plasma cells, granulocytes outside of abscesses) for prediction of atezolizumab efficacy in triple-negative metastatic breast cancer.

Metastatic or primary tumor tissue

2	A	++
---	---	----

Detection with antibodies equivalent to Impassion 130 study reagents

3	B	+
---	---	---

Combined positive score (CPS): positive cells (tumor cells, lymphocytes, and macrophages) divided by the total number of tumor cells multiplied by 100 ($\geq 10 =$ positive) for prediction of pembrolizumab efficacy in metastatic triple-negative breast cancer.

2	A	++
---	---	----

Mutation Diagnostics* in mBC: „Precision Medicine“ for Targeted Therapies

© AGO e. V.
in der DGGG e.V.
sowie
in der DKG e.V.

Guidelines Breast
Version 2022.2E

Altered genes	Therapeutic relevance	Gene region	Material	Oxford		
				LOE	GR	AGO
BRCA1, BRCA2	PARP-Inhibitors	All exons	Germline: Blood cells	1b	A	++
			Somatic: Tissue	2b	B	+/-
PALB2	PARP-Inhibitors		Germline: Blood cells	2b	B	+
PIK3CA	Alpelisib	Exons 7,9 and 20	Primary tumor, metastases, plasma	1b	A	++
HER2-mutation (independent of HER2- status)	Neratinib, lapatinib	Kinase- and extracellular domains; S310, L755, V777, Y772_A775dup	Primary tumor, metastases, plasma particul. lobular BC	4	C	+/-
ESR1	Resistance against AI	Exons 4,7 und 8	Metastases, plasma	2b	B	+/-
NTRK gene fusion	Larotrectinib, entrectinib	Fusion- and splice variants	Tumor tissue, particul. secretory breast cancer	2a	B	+
MSI	Pembrolizumab	Microsatellite-instability	Tissue	2a	B	+

* Ideally panel diagnostics