



© AGO e. V.
in der DGGG e.V.
sowie
in der DKG e.V.

Guidelines Breast
Version 2025.1E

www.ago-online.de

FORSCHEN
LEHREN
HEILEN

Diagnosis and Treatment of Patients with early and advanced Breast Cancer

Ductal Carcinoma in Situ (DCIS)



© AGO e. V.
in der DGGG e.V.
sowie
in der DKG e.V.

Guidelines Breast
Version 2025.1E

www.ago-online.de

FORSCHEN
LEHREN
HEILEN

Ductal Carcinoma In Situ (DCIS)

- **Versions 2002–2024:**

Audretsch / Bauerfeind / Blohmer / Brunnert / Budach / Costa / Ditsch /
Fersis / Friedrich / Gerber / Hanf / Junkermann / Kühn / Lux / Maass /
Möbus / Mundhenke / Nitz / Oberhoff / Scharl / Schütz / Solbach /
Solomayer / Souchon / Thill / Thomssen / Wenz

- **Version 2025:**

Gluz / Kuemmel

DCIS - Pretherapeutic Assessment

	Oxford		
	LoE	GR	AGO
▪ Mammography	1b	B	++
▪ Magnification view of microcalcifications	4	C	++
▪ Increased detection rate of G1 / G2 DCIS by full-field digital mammography (versus screen-film)	2b	B	+
▪ Ultrasound (to rule out an accompanying invasive component)	4	C	++
▪ For tumors with a solid part	4	C	++
▪ MRI to determine the extension and planning of surgery	1a	B	+/-
▪ Clinical examination	5	D	++
▪ Stereotactic core needle / vacuum biopsy (VAB)	2b	B	++
▪ Specimen radiography	2b	B	++
▪ Marker (clip) left at biopsy site for localization if lesion is completely removed	5	D	++
▪ Interdisciplinary board presentation	5	D	++

Mammographie

1. Li J, Zhang H, Jiang H, Guo X et al. Diagnostic Performance of Digital Breast Tomosynthesis for Breast Suspicious Calcifications From Various Populations: A Comparison With Full-field Digital Mammography. *Comput Struct Biotechnol J*. 2018 Dec 20;17:82-89.
2. Adachi M, Fujioka T, Mori M et al. Detection and Diagnosis of Breast Cancer Using Artificial Intelligence Based Assessment of Maximum Intensity Projection Dynamic Contrast-Enhanced Magnetic Resonance Images. *Diagnostics (Basel)* 2020 May; 10(5): 330. Published online 2020 May 20. doi: 10.3390/diagnostics10050330
3. Sanmugasiva VV, Hamid MTR, Fadzli F, et al. Diagnostic accuracy of digital breast tomosynthesis in combination with 2D mammography for the characterisation of mammographic abnormalities. *Sci Rep*. 2020; 10: 20628. Published online 2020 Nov 26. doi: 10.1038/s41598-020-77456-6
4. Schaffter T, Buist DSM, Lee CI, et al. Evaluation of Combined Artificial Intelligence and Radiologist Assessment to Interpret Screening Mammograms. *JAMA Netw Open*. 2020 Mar; 3(3): e200265. Published online 2020 Mar 2. doi: 10.1001/jamanetworkopen.2020.0265


Präoperatives MRT

1. Vapiwala N, Hwang WT, Kushner CJ, et al. No impact of breast magnetic resonance imaging on 15-year outcomes in patients with ductal carcinoma in situ or early-stage invasive breast cancer managed with breast conservation therapy. *Cancer*. 2017;123(8):1324-1332.
2. Ryan R, Tawfik O, Jensen RA et al. Current Approaches to Diagnosis and Treatment of Ductal Carcinoma In Situ and Future Directions. *Prog Mol Biol Transl Sci*. 2017;151:33-80.
3. Preibsch H, Beckmann J, Pawlowski J et al. Accuracy of Breast Magnetic Resonance Imaging Compared to Mammography in the Preoperative Detection and Measurement of Pure Ductal Carcinoma In Situ: A Retrospective *Radiol*. 2018 Aug 24. pii: S1076-6332(18)30383-0.
4. So A, De La Cruz LM, Williams AD et al. impact of preoperative magnetic resonance imaging and lumpectomy cavity shavings on re-excision rate in pure ductal carcinoma in situ-A single institution's experience. *J Surg Oncol*. 2018 Mar;117(4):558-566.
5. Lamb LR, Oseni TO, Lehman CD et al. Pre-operative MRI in patients with ductal carcinoma in situ: Is MRI useful for identifying additional disease? *Eur J Radiol*. 2020 Aug;129:109130. doi: 10.1016/j.ejrad.2020.109130.
6. Lam DL, Smith J, Partridge S et al. The Impact of Preoperative Breast MRI on Surgical Management of Women with Newly Diagnosed Ductal Carcinoma In Situ. *Acad Radiol*. 2020 Apr;27(4):478-486. doi: 10.1016/j.acra.2019.05.013.
7. Lee J, Jung JH, Kim WW et al. Efficacy of breast MRI for surgical decision in patients with breast cancer: ductal carcinoma in situ versus invasive ductal carcinoma. *BMC Cancer*. 2020 Sep 29;20(1):934. doi: 10.1186/s12885-020-07443-7.
8. Canelo-Aybar C, Taype-Rondan A, Zafra-Tanaka JH, et al: Preoperative breast magnetic resonance imaging in patients with ductal carcinoma in situ: a systematic review for the European Commission Initiative on Breast Cancer (ECIBC). *Eur Radiol*. 2021 Aug;31(8):5880-5893. doi: 10.1007/s00330-021-07873-2.
9. Chou SHS, Romanoff J, Lehmann CD: Preoperative Breast MRI for Newly Diagnosed Ductal Carcinoma in Situ: Imaging Features and Performance in a Multicenter Setting (ECOG-ACRIN E4112 Trial). *Radiology*, 2021 Oct;301(1):66-77. doi: 10.1148/radiol.2021204743. Epub 2021 Aug 3.

Sonographie

1. Watanabe T, Yamaguchi T, Tsunoda H, et al. Ultrasound image classification of ductal carcinoma in situ (DCIS) of the breast: Analysis of 705 DCIS lesions. *Ultrasound Med Biol*. 2017;43:918–25.
2. Bragg A, Candelaria R, et al: Imaging of Noncalcified Ductal Carcinoma In Situ *J Clin Imaging Sci*. 2021 Jun 16;11:34. doi: 10.25259/JCIS_48_2021

3. Grimm L, Rahbar H, Abdelmalak M et al.: Ductal Carcinoma in Situ: State-of-the-Art Review. Radiology . 2021 Dec 21;211839.
4. Rauch GM, Kuerer HM, et al: Clinicopathologic, mammographic, and sonographic features in 1,187 patients with pure ductal carcinoma in situ of the breast by estrogen receptor status. Breast Cancer Res Treat. 2013 Jun; 139(3):639-47.



© AGO e. V.
in der DGGG e.V.
sowie
in der DKG e.V.

Guidelines Breast
Version 2025.1E

www.ago-online.de
FORSCHEN
LEHREN
HEILEN

DCIS – Upstaging, ipsi- / Contralateral Events und Mortality

Upstaging to BC %	Ipsilateral events (cum. incidence) %	Contralateral events (cum. incidence) %	BC-specific mortality % (95% CI)
5-25.9	10 years: BCS: 24.6 BCS and radiotherapy: 9.6 20 years: BCS: 30.6 BCS and radiotherapy: 18.2	10 years: 4.8-6.4 15 years: 6.4~11	10 years: 0.9 (0.7-1.1) (BCS) 0.8 (0.7-1.0) (BCS and radiotherapy) 1.3 (1.1-1.5) (unilateral mastectomy)

~ 50% of all ipsilateral events are invasive.
Breast cancer specific mortality is 3,3%.
Women with DCIS have a 1.8-3-fold increased risk of death compared to normal population/women without DCIS. Risk is greater for young and black women.

Upstaging

1. Brennan ME, Turner RM, Ciatto S, et al. Ductal carcinoma in situ at coreneedle biopsy: meta-analysis of underestimation and predictors of invasive breast cancer. *Radiology* 2011;260(1):119–128.
2. Oseni TO, Smith BL, Lehman CD, et al: Do Eligibility Criteria for Ductal Carcinoma In Situ (DCIS) Active Surveillance Trials Identify Patients at Low Risk for Upgrade to Invasive Carcinoma? *Ann Surg Oncol.* 2020 Oct;27(11):4459-4465. doi: 10.1245/s10434-020-08576-6..

Ipsilateral

1. Narod SA, Iqbal J, Giannakeas V, et al. Breast Cancer Mortality After a Diagnosis of Ductal Carcinoma In Situ. *JAMA Oncol.* 2015 Oct;1(7):888-96
2. Giannakeas V, Sopik V, Narod SA. et al. Association of a Diagnosis of Ductal Carcinoma In Situ With Death From Breast Cancer. *JAMA Netw Open.* 2020 Sep 1;3(9):e2017124. doi: 10.1001/jamanetworkopen.2020.17124
3. Mannu GS, Wang Z, Broggio J, et al: Invasive breast cancer and breast cancer mortality after ductal carcinoma in situ in women attending for breast screening in England, 1988-2014: population based observational cohort

study. BMJ. 2020 May 27;369:m1570.

4. van Seijen M , Lips EH , Fu L: Long-term risk of subsequent ipsilateral lesions after surgery with or without radiotherapy for ductal carcinoma in situ of the breast. British Journal of Cancer (2021) 125:1443–1449; <https://doi.org/10.1038/s41416-021-01496-6>


Kontralateral

1. Wärnberg F, Garmo H, Emdin St: Effect of Radiotherapy After Breast-Conserving Surgery for Ductal Carcinoma in Situ: 20 Years Follow-Up in the Randomized SweDCIS Trial. JCO, 32: 32, 2014
2. Elshof LE, Schaapveld M, Schmidt MK: Subsequent risk of ipsilateral and contralateral invasive breast cancer after treatment for ductal carcinoma in situ: incidence and the effect of radiotherapy in a population-based cohort of 10,090 women. Breast Cancer Res Treat. 2016; 159(3): 553–563.
3. Miller ME , Muhsen, Zabor EC, et al: Risk of Contralateral Breast Cancer in Women with Ductal Carcinoma In Situ Associated with Synchronous Ipsilateral Lobular Carcinoma In Situ. Ann Surg Oncol. 2019 Dec;26(13):4317-4325. doi: 10.1245/s10434-019-07796-9.
4. Giardiella D, Kramer I, Maartje J, et al: Contralateral breast cancer risk in pts with ductal carcinoma in situ and invasive breast cancer. Npj Breast Cancer 6:60, 2020
5. Hovis K, Mercaldo S, Kim G: Contralateral breast cancer after curative-intent treatment for ductal carcinoma in situ: Rate and associated clinicopathological and imaging risk factors. Clin Imaging. 2021 Nov 20;82:179-192. doi: 10.1016/j.clinimag.2021.11.018.


Überleben

1. Narod SA, Iqbal J, Giannakeas V, et al. Breast Cancer Mortality After a Diagnosis of Ductal Carcinoma In Situ. JAMA Oncol. 2015 Oct;1(7):888-96

2. Giannakeas V, Sopik V, Narod SA. et al. Association of a Diagnosis of Ductal Carcinoma In Situ With Death From Breast Cancer. *JAMA Netw Open*. 2020 Sep 1;3(9):e2017124. doi: 10.1001/jamanetworkopen.2020.17124



ARBEITSGEMEINSCHAFT
STRAHLENTHERAPEUTISCHE
ONKOLOGIE E.V.



MAMMA

© AGO e. V.,
in der DGGG e.V.,
sowie
in der DKG e.V.

Guidelines Breast
Version 2025.1E

www.ago-online.de

FORSCHEN
LEHREN
HEILEN

Association of a Diagnosis of Ductal Carcinoma In Situ With Death From Breast Cancer


Giannakeas V, Sopik V, Narod SA. JAMA Netw Open. 2020 Sep 1;3(9):e2017124

- **144,524 women treated for DCIS, 1,540 women died of breast cancer,**
- **cohort study included data for women who had first primary DCIS diagnosed between 1995 and 2014 from the SEER registries database (use of ET is not reported),**
- **retrospective analysis,**
- **results:**
 - **standardized mortality ratio for death from breast cancer among women with DCIS was 3.36 (95% CI, 3.20-3.53),**
 - **risk is greater for young and black women,**
 - **4,502 (3.1%) ipsilateral invasive recurrences, resulting in a 20-year actuarial risk of 13.9%,**
 - **5,527 (3.8%) contralateral invasive breast cancers, resulting in a 20-year actuarial risk of 11.3%,**
 - **women with DCIS had a 3-fold increased risk of death from breast cancer compared to women without DCIS.**

1. Giannakeas V, Sopik V, Narod SA. et al. Association of a Diagnosis of Ductal Carcinoma In Situ With Death From Breast Cancer. JAMA Netw Open. 2020 Sep 1;3(9):e2017124. doi: 10.1001/jamanetworkopen.2020.17124.

Risk Factors for Upstaging from DCIS to Invasive Cancer in Final Surgical Specimen		Oxford
		LoE
Higher risk		
▪ DCIS without microcalcification in core needle or vacuum biopsy		3b
▪ Microcalcification $\geq 11,5$ mm		3b
▪ Presentation as tumor in MRI		3b
▪ Increased Ki-67 ($\geq 20\%$)		3b
▪ PR negative		3b
▪ High peak contrast enhancement on MRI		3b
▪ Irregularly shaped, non-circumscribed, heterogeneous or margin-enhancing tumors with intratumoral high signal intensity or peritumoral edema on MRI		3b
▪ Biopsy technique: diagnosis by core needle biopsy versus vacuum biopsy (smaller sampling volume)		3b
▪ High platelet-lymphocyte ratio		3b
Lower risk		
▪ Removal $\geq 90\%$ of the microcalcifications by vacuum biopsy		3b

1. Cheung YC, Chen SC, Ueng SH, et al. Ductal Carcinoma In Situ Underestimation of Microcalcifications Only by Stereotactic Vacuum-Assisted Breast Biopsy: A New Predictor of Specimens without Microcalcifications. J Clin Med. 2020 Sep; 9(9): 2999. Published online 2020 Sep 17. doi: 10.3390/jcm9092999
2. Visser LL, Elshof LE, Van de Vijver K, et al. Discordant Marker Expression Between Invasive Breast Carcinoma and Corresponding Synchronous and Preceding DCIS. Am J Surg Pathol 2019;43(11):1574–1582.
3. Yoon GY, Choi WJ, Cha JH, et al. The role of MRI and clinicopathologic features in predicting the invasive component of biopsy-confirmed ductal carcinoma in situ. BMC Med Imaging. 2020; 20: 95. Published online 2020 Aug 12. doi: 10.1186/s12880-020-00494-z
4. Takada K, Kashiwagi S, Asano Y, et al. Factors predictive of invasive ductal carcinoma in cases preoperatively diagnosed as ductal carcinoma in situ. BMC Cancer. 2020; 20: 513. Published online 2020 Jun 3. doi: 10.1186/s12885-020-07001-



Good Clinical Practice (GCP)

Surgical excision (BCS or mastectomy) is the standard treatment for DCIS.

Adjuvant treatment (radiotherapy, endocrine treatment) must be discussed with the patient individually. Adverse effects should be weighted against risk reduction.

1. Kirsty E. Stuart, Nehmat Houssami, Richard Taylor, et al. Long-term outcomes of ductal carcinoma in situ of the breast: a systematic review, meta-analysis and meta-regression analysis. *BMC Cancer* (2015) 15:890.
2. Katrina B. Mitchell and Henry Kuerer. Ductal Carcinoma In Situ: Treatment Update and Current Trends. *Curr Oncol Rep* (2015) 17: 48
3. Elizabeth M. Ward, Carol E. DeSantis, Chun Chieh Lin, et al. Cancer Statistics: Breast Cancer In Situ. *CA Cancer J Clin* 2015;65:481–495.
4. Benjamin D. Smith. When Is Good Enough Really Good Enough? Defining the Role of Radiation in Low-Risk Ductal Carcinoma In Situ. *J Clin Oncol* 2015; 33(7): 686 – 692.
5. Laura Esserman, Christina Yau. Rethinking the Standard for Ductal Carcinoma In Situ Treatment. *JAMA Oncology* Published online August 20, 2015.
6. Steven A. Narod, Javaid Iqbal, Vasily Giannakeas, et al. Breast Cancer Mortality After a Diagnosis of Ductal Carcinoma In Situ. *JAMA Oncol*. doi:10.1001/jamaoncol.2015.2510 Published online August 20, 2015.
7. Hamilton SN, Nichol A, Wai E et al. Local Relapse After Breast-Conserving Therapy Versus Mastectomy for Extensive Pure Ductal Carcinoma In Situ ≥ 4 cm. *Int J Radiat Oncol Biol Phys*. 2018 Sep 22. pii: S0360-3016(18)33801-X
8. Gradishar WJ, Anderson BO, Balassanian R et al. Breast Cancer, Version 4.2017, NCCN Clinical Practice Guidelines in Oncology. *J Natl Compr Canc Netw*. 2018 Mar;16(3):310-320.

Surgical Treatment for Histologically Proven DCIS I

	Oxford		
	LoE	GR	AGO
▪ Excisional biopsy (wire guided)	2b	B	++
▪ Localization with wire-free procedure	3b	C	+/-
▪ Bracketing wire localization in large lesions	3a	C	+
▪ Specimen radiography	2b	B	++
▪ Intraoperative ultrasound (pre-op visible lesion)	3a	C	+/-
▪ Immediate re-excision in case of incomplete resection (specimen radiography)	1c	B	++
▪ Intraoperative frozen section (in individual cases for margin assessment)	3a	D	+/-
▪ Interdisciplinary board presentation	2b	C	++
▪ For low-risk DCIS (>=40 yrs, HR+, G1,2) - Active monitoring* without surgery (COMET study)	2a	B	-

Open biopsy in suspicious lesions (mammographic microcalcifications, suspicious US, MRI etc.) without preoperative needle biopsy should be avoided

* Mammography of the affected side every 6 months

Exzision (drahtmarkiert)

1. Houssami N, Ambrogetti D, Marinovich L et al. Accuracy of a preoperative model for predicting invasive breast cancer in women with ductal carcinoma in situ on vacuum assisted core needle biopsy. *Ann Surg Oncol* 2011;18(5):1364-71
2. Ryan R, Tawfik O, Jensen RA, et al. Current Approaches to Diagnosis and Treatment of Ductal Carcinoma In Situ and Future Directions. *Prog Mol Biol Transl Sci.* 2017;151:33-80.
3. Janssen NNY, van la Parra RFD, Loo CE et al. Breast conserving surgery for extensive DCIS using multiple radioactive seeds. *Eur J Surg Oncol.* 2018 Jan;44(1):67-73.
4. Hong YK, McMasters KM, Egger ME, et al. Ductal carcinoma in situ current trends, controversies, and review of literature. *Am J Surg.* 2018 Nov;216(5):998-1003
5. Kuerer HM, Smith BD, Chavez-MacGregor M, et al. DCIS Margins and Breast Conservation: MD Anderson Cancer Center Multidisciplinary Practice Guidelines and Outcomes. *J Cancer.* 2017;8(14):2653-2662.
6. DVerstehenden DPA, Keizer LGG, Schlooz-Vries MS, et al: Performance characteristics of specimen radiography for margin assessment for ductal carcinoma in situ: a systematic review. *Breast Cancer Res Treat* 2017;166:669–679.
7. Pieszko K, Wichtowski M, Cieciorowski M, et al. Evaluation of the nonradioactive inducible magnetic seed system Magseed for preoperative localization of nonpalpable breast lesions – initial clinical experience *Contemp Oncol (Pozn)* 2020; 24(1): 51–54. Published online 2020 Mar 13. doi: 10.5114/wo.2020.93677

8. Colombe Agahozo M, Berghuis SAM, van den Broek E, et al. Radioactive Seed Versus Wire-Guided Localization for Ductal Carcinoma in Situ of the Breast: Comparable Resection Margins. *Ann Surg Oncol*. 2020; 27(13): 5296–5302. Published online 2020 Jun 23. doi: 10.1245/s10434-020-08744-8

Intraoperative Sonographie (darstellbarer Befund)

1. Ahmed M, Douek M. Intra-operative ultrasound versus wire-guided localization in the surgical management of non-palpable breast cancers: systematic review and meta-analysis. *Breast Cancer Res Treat*. 2013; 140(3): 435-446.

Sofortige Nachresektion bei knappen Resektionsrändern (Präparateradiographie)

1. Thill M, Dittmer C, Baumann K, et al. MarginProbe®--final results of the German post-market study in breast conserving surgery of ductal carcinoma in situ. *Breast*. 2014 Feb;23(1):94-6. doi: 10.1016/j.breast.2013.11.002. Epub 2013 Dec 2.
2. Kuerer HM, Smith BD, Chavez-MacGregor M, et al. DCIS Margins and Breast Conservation: MD Anderson Cancer Center Multidisciplinary Practice Guidelines and Outcomes. *J Cancer*. 2017;8(14):2653-2662.

Intraoperative Schnellschnittdiagnostik

1. Kuerer HM, Smith BD, Chavez-MacGregor M et al. DCIS Margins and Breast Conservation: MD Anderson Cancer Center Multidisciplinary Practice Guidelines and Outcomes. *J Cancer*. 2017;8(14):2653-2662.
2. Laws A, Brar MS, Bouchard-Fortier A, et al. surgery for ductal carcinoma in situ. *J Surg Oncol*. 2018 Dec;118(7):1205-1211.
3. Morrow M, Van Zee KJ, Solin LJ, Houssami N et al: Society of Surgical Oncology-American Society for Radiation Oncology-American Society of Clinical Oncology Consensus Guideline on Margins for Breast-Conserving Surgery with Whole-Breast Irradiation in Ductal Carcinoma In Situ. *Ann Surg Oncol*. 2016 Nov;23(12):3801-3810.

Statement: Non-palpable lesions or lesions

1. Morrow M, Strom E, Bassett L et al. Standard for the management of ductal carcinoma in situ of the breast (DCIS). *CA Cancer J Clin* 2002; 52: 256-276.

Tumorboard

1. Farante G, Toesca A, Magnoni F, et al: Advances and controversies in management of breast ductal carcinoma in situ (DCIS). PMID: 34772587, DOI: 10.1016/j.ejso.2021.10.030

Active Monitoring

1. Hwang ES, Hyslop T, Lynch T, et al: Active Monitoring With or Without Endocrine Therapy for Low-Risk Ductal Carcinoma In Situ. The COMET Randomized Clinical Trial. *JAMA*. doi:10.1001/jama.2024.26698
2. Qian C., Campbell I., Elwood M., et al: Outcomes from low-risk ductal carcinoma in situ: a systematic review and meta-analysis. *Breast Cancer Research and Treatment* (2024) 208:237–251.
3. Elizabeth C.P., Dong W., Shaitelma S.F., et al: Survival outcomes after omission of surgery for ductal carcinoma in situ. npj | breast cancer. <https://doi.org/10.1038/s41523-024-00689-5>



© AGO e. V.
in der DGGG e.V.
sowie
in der DKG e.V.
Guidelines Breast
Version 2025.1E

www.ago-online.de

FORSCHEN
LEHREN
HEILEN

Active Monitoring With or Without Endocrine Therapy for Low-Risk Ductal Carcinoma In Situ - The COMET Randomized Clinical Trial

Prospective, randomized noninferiority trial enrolling 995 women:

- DCIS Grade 1 (ca. 25%) , Grade 2 (ca.75%)
- Median Age 63.6-7 yrs. in both groups, ER+ (97.7-98.7%),
- Median Follow up 36.9 months (the 2-year Kaplan-Meier cumulative rate of ipsilateral invasive cancer was 5.9% in the guideline-concordant care group vs 4.2% in the active monitoring group).

Table 3. Treatment Received Within 24 Months

Treatment within 24 mo	No. (%)	
	Active monitoring (n = 484)	Guideline-concordant care (n = 473)
Any endocrine therapy	345 (71.3)	310 (65.5)
Any radiotherapy	36 (7.4)	126 (26.6)
Any chemotherapy	6 (1.2)	5 (1.1)
Type of surgery	n = 82	n = 264
Lumpectomy	64 (13.2)	228 (48.2)
Mastectomy	18 (3.7)	26 (5.5)
Reexcision	0	10 (2.1)

Hwang E.S. et al., JAMA. doi:10.1001/jama.2024.26698

Upstaging

1. Brennan ME, Turner RM, Ciatto S, et al. Ductal carcinoma in situ at coreneedle biopsy: meta-analysis of underestimation and predictors of invasive breast cancer. *Radiology* 2011;260(1):119–128.
2. Oseni TO, Smith BL, Lehman CD, et al: Do Eligibility Criteria for Ductal Carcinoma In Situ (DCIS) Active Surveillance Trials Identify Patients at Low Risk for Upgrade to Invasive Carcinoma? *Ann Surg Oncol.* 2020 Oct;27(11):4459-4465. doi: 10.1245/s10434-020-08576-6..

Ipsilateral

1. Narod SA, Iqbal J, Giannakeas V, et al. Breast Cancer Mortality After a Diagnosis of Ductal Carcinoma In Situ. *JAMA Oncol.* 2015 Oct;1(7):888-96
2. Giannakeas V, Sopik V, Narod SA. et al. Association of a Diagnosis of Ductal Carcinoma In Situ With Death From Breast Cancer. *JAMA Netw Open.* 2020 Sep 1;3(9):e2017124. doi: 10.1001/jamanetworkopen.2020.17124
3. Mannu GS, Wang Z, Broggio J, et al: Invasive breast cancer and breast cancer mortality after ductal carcinoma in situ in women attending for breast screening in England, 1988-2014: population based observational cohort study. *BMJ.* 2020

May 27;369:m1570.

4. van Seijen M , Lips EH , Fu L: Long-term risk of subsequent ipsilateral lesions after surgery with or without radiotherapy for ductal carcinoma in situ of the breast. *British Journal of Cancer* (2021) 125:1443–1449; <https://doi.org/10.1038/s41416-021-01496-6>

Kontralateral

1. Wärnberg F, Garmo H, Emdin St: Effect of Radiotherapy After Breast-Conserving Surgery for Ductal Carcinoma in Situ: 20 Years Follow-Up in the Randomized SweDCIS Trial. *JCO*, 32: 32, 2014
2. Elshof LE, Schaapveld M, Schmidt MK: Subsequent risk of ipsilateral and contralateral invasive breast cancer after treatment for ductal carcinoma in situ: incidence and the effect of radiotherapy in a population-based cohort of 10,090 women. *Breast Cancer Res Treat.* 2016; 159(3): 553–563.
3. Miller ME , Muhsen, Zabor EC, et al: Risk of Contralateral Breast Cancer in Women with Ductal Carcinoma In Situ Associated with Synchronous Ipsilateral Lobular Carcinoma In Situ. *Ann Surg Oncol.* 2019 Dec;26(13):4317-4325. doi: 10.1245/s10434-019-07796-9.
4. Giardiella D, Kramer I, Maartje J, et al: Contralateral breast cancer risk in pts with ductal carcinoma in situ and invasive breast cancer. *Npj Breast Cancer* 6:60, 2020
5. Hovis K, Mercaldo S, Kim G: Contralateral breast cancer after curative-intent treatment for ductal carcinoma in situ: Rate and associated clinicopathological and imaging risk factors. *Clin Imaging.* 2021 Nov 20;82:179-192. doi: 10.1016/j.clinimag.2021.11.018.

Überleben

1. Narod SA, Iqbal J, Giannakeas V, et al. Breast Cancer Mortality After a Diagnosis of Ductal Carcinoma In Situ. *JAMA Oncol.* 2015 Oct;1(7):888-96
2. Giannakeas V, Sopik V, Narod SA. et al. Association of a Diagnosis of Ductal Carcinoma In Situ With Death From Breast

Cancer. JAMA Netw Open. 2020 Sep 1;3(9):e2017124. doi: 10.1001/jamanetworkopen.2020.17124

Surgical Treatment for Histologically Proven DCIS II

	Oxford		
	LoE	GR	AGO
▪ Histologically clear margins (Ris0)	1a	A	++
▪ Multifocal DCIS: BCS if feasible	2b	B	+
▪ Re-excision required for close margin in case of BCS and radiotherapy (≤ 2 mm in paraffin section)*	2b	C	+
▪ Mastectomy**			
▪ Large lesions confirmed by multiple biopsies; no clear margins after re-excision	2a	B	++
▪ SLNE			
▪ Mastectomy	3b	B	+
▪ BCS	3b	B	--
▪ In case of DCIS in the male breast	5	D	+/-
▪ ALND	2b	B	--

* Individual approach taking into account age, tumor size, grading and implementation of radiation, especially in case of no subsequent radiation
 ** Patients who present with a palpable mass have a significantly higher potential for occult invasion (26%), multicentricity and local recurrence

Histologisch freie Resektionsränder (pR0)

1. Badruddoja M. Ductal carcinoma in situ of the breast: a surgical perspective. Int J Surg Oncol. 2012;2012:761364. doi: 10.1155/2012/761364. Epub 2012 Sep 4.
2. Hassani A, Griffith C, Harvey J. Size does matter: High volume breast surgeons accept smaller excision margins for wide local excision--a national survey of the surgical management of wide local excision margins in UK breast cancer patients. Breast. 2013 Oct;22(5):718-22.
3. Morrow M., et al: Society of Surgical Oncology –American Society for Radiation Oncology–American Society of Clinical Oncology Consensus Guideline on Margins for Breast-Conserving Surgery with Whole-Breast Irradiation in Ductal Carcinoma in Situ J CO 2016 34;33 :4040-4046
4. Salvatorelli L, Puzzo L, Vecchio GM, et al. Ductal Carcinoma In Situ of the Breast: An Update with Emphasis on Radiological and Morphological Features as Predictive Prognostic Factors. Cancers (Basel) 2020 Mar; 12(3): 609. Published online 2020 Mar 6. doi: 10.3390/cancers12030609
5. Livingston-Rosanoff D, Trentham-Dietz A, Hampton JM, et al: Does margin width impact breast cancer recurrence rates in women with breast conserving surgery for ductal carcinoma in situ? Breast Cancer Res Treat. 2021 Sep;189(2):463-470. doi: 10.1007/s10549-021-06278-5.

Multifokalität: BET falls möglich (inkl. RT)

1. Meijnen P, Bartelink H. Multifocal ductal carcinoma in situ of the breast: A contraindication for breast-conserving treatment? J Clin Oncol 2007;25:5548–5549
2. Rakovitch E, Pignol JP, Hanna W, et al. Significance of multifocality in ductal carcinoma in situ: outcomes of women treated with breast-conserving therapy. J Clin Oncol 2007;25:5591–5596

Nachresektion bei knappem Resektionsrand (< 2 mm im Paraffinschnitt)

1. Dunne, C., J. P. Burke, et al. (2009). "Effect of margin status on local recurrence after breast conservation and radiation therapy for ductal carcinoma in situ." J Clin Oncol 27(10): 1615-1620.
2. Van Cleef A, Altintas S, Huizing M et al. Current view on ductal carcinoma in situ and importance of the margin thresholds: A review. Facts Views Vis Obgyn. 2014;6(4):210-8.
3. Kuerer HM, Smith BD, Chavez-MacGregor M et al. DCIS Margins and Breast Conservation: MD Anderson Cancer Center Multidisciplinary Practice Guidelines and Outcomes. J Cancer. 2017;8(14):2653-2662.
4. Morrow M. De-escalating and escalating surgery in the management of early breast cancer. Breast. 2017 Aug;34 Suppl 1:S1-S4.

Mastektomie* (große Läsionen; keine sicheren Ränder im Nachresektat)

1. Carlson, G. W., A. Page, et al. (2007). "Local recurrence of ductal carcinoma in situ after skin-sparing mastectomy." J Am Coll Surg 204(5): 1074-1078; discussion 1078-1080.
2. Rudloff U, E Brogi et al. (2010): "The Influence of Margin Width and Volume of Disease Near Margin on Benefit of Radiation Therapy for Women With DCIS Treated With Breast-Conserving Therapy" Ann Surg (251) 583 – 591
3. Polyak K. Molecular markers for the diagnosis and management of ductal carcinoma in situ. J Natl Cancer Inst Monogr 2010; 41: 210-213
4. Houssami N, Ambrogetti D, Marinovich L et al. Accuracy of a preoperative model for predicting invasive breast cancer in women with ductal carcinoma in situ on vacuum assisted core needle biopsy. Ann Surg Oncol 2011;18(5):1364-71

SLNE* /Axilladissektion

1. Killelea BK, Long JB, Dang W, et al. Associations Between Sentinel Lymph Node Biopsy and Complications for Patients

with Ductal Carcinoma In Situ. *Ann Surg Oncol*. 2018 Jun;25(6):1521-1529.


2. Hong YK, McMasters KM, Egger ME, et al. Ductal carcinoma in situ current trends, controversies, and review of literature. *Am J Surg*. 2018 Nov;216(5):998-1003
3. Karakatsanis A, Hersi AF, Pistiolis L: Effect of preoperative injection of superparamagnetic iron oxide particles on rates of sentinel lymph node dissection in women undergoing surgery for ductal carcinoma in situ (SentiNot study). *Br J Surg*. 2019 May;106(6):720-728. doi: 10.1002/bjs.11110. Epub 2019 Mar 6.
4. Price A, Schnabel F, Chun J et al. Sentinel lymph node positivity in patients undergoing mastectomies for ductal carcinoma in situ (DCIS). *Breast J*. 2020 May;26(5):931-936. doi: 10.1111/tbj.13737.
5. Pyfer BJ, Jonczyk M, Jean J et al. Analysis of Surgical Trends for Axillary Lymph Node Management in Patients with Ductal Carcinoma In Situ Using the NSQIP Database: Are We Following National Guidelines? *Ann Surg Oncol*. 2020 Sep;27(9):3448-3455. doi: 10.1245/s10434-020-08374-0

DCIS beim Mann

1. Chern J, Liao L, Baraldi R, et al. Case report: ductal carcinoma in situ in the male breast. *Case Rep Radiol*. 2012;2012:532527. doi: 10.1155/2012/532527. Epub 2012 Sep 26.

BET

1. Meijnen P, Oldenburg HS, Loo CE, et al. Risk of invasion and axillary lymph node metastasis in ductal carcinoma in situ diagnosed by core-needle biopsy. *Br J Surg* 2007;94:952-6
2. Miyake T, Shimazu K, Ohashi H, et al. Indication for sentinel lymph node biopsy for breast cancer when core biopsy shows ductal carcinoma in situ. *The American Journal of Surgery* 2011; 202: 59-65 :394095. doi: 10.5402/2012/394095. Epub 2012 May 14.
3. De Lorenzi F, Di Bella J, Maisonneuve P et al. Oncoplastic breast surgery for the management of ductal carcinoma in situ (DCIS): is it oncologically safe? A retrospective cohort analysis. *Eur J Surg Oncol*. 2018 Jul;44(7):957-962



Prognostic Factors for an Ipsilateral Recurrence after DCIS I

	LoE
▪ Resection margins	1a
▪ Age	1a
▪ Size	1a
▪ Grade	1a
▪ Comedo necrosis	1a
▪ Method of diagnosis	1a
▪ Focality	1a
▪ HER2-overexpression	1a
▪ ER / PR (positive vs. negative)	1a

See also chapter "Prognostic Faktoren"

1. Visser LL, Elshof LE, Schaapveld M et al. Clinicopathological Risk Factors for an Invasive Breast Cancer recurrence after Ductal Carcinoma In Situ-A Nested Case-Control Study. Clin Cancer Res. 2018 Aug 1;24(15):3593-3601.
2. Rakovitch E, Gray R, Baehner FL et al. Refined estimates of local recurrence risks by DCIS score adjusting for clinicopathological features: a combined analysis of ECOG-ACRIN E5194 and Ontario DCIS cohort studies. Breast Cancer Res Treat. 2018 Jun;169(2):359-369
3. Cutuli B: Ductal carcinoma in situ in 2019: Diagnosis, treatment, prognosis. Presse Med. 2019 Oct;48(10):1112-1122
4. Badve SS, Gökmen-Polar: Ductal carcinoma in situ of breast: update 2019. Pathology. 2019 Oct;51(6):563-569.
5. Van Bockstal MR, Agahozo MC, Koppert LB: A retrospective alternative for active surveillance trials for ductal carcinoma in situ of the breast. Int J Cancer. 2020 Mar 1;146(5):1189-1197
6. Solin LJ: Management of Ductal Carcinoma In Situ (DCIS) of the Breast: Present Approaches and Future Directions. Curr Oncol Rep. 2019 Mar 5;21(4):33
7. Giannakeas V, Sopik V, Narod SA. Association of a Diagnosis of Ductal Carcinoma In Situ With Death From Breast Cancer. JAMA Netw Open. 2020 Sep; 3(9): e2017124. Published online 2020 Sep 16. doi: 10.1001/jamanetworkopen.2020.17124
8. Groen EJ, Hudecek J, Mulder L, et al. Prognostic value of histopathological DCIS features in a large-scale international interrater reliability study. Breast Cancer Res Treat. 2020; 183(3): 759–770. Published online 2020 Jul 30. doi:

10.1007/s10549-020-05816-x

Diagnostische Methode

1. Park HS, Park S, Cho J, et al. Risk predictors of underestimation and the need for sentinel node biopsy in patients diagnosed with ductal carcinoma in situ by preoperative needle biopsy. *J Surg Oncol*. 2013 Mar;107(4):388-92. doi: 10.1002/jso.23273. Epub 2012 Sep 24.
2. Schulz S, Sinn P, Golatta M, et al. Prediction of underestimated invasiveness in patients with ductal carcinoma in situ of the breast on percutaneous biopsy as rationale for recommending concurrent sentinel lymph node biopsy. *Breast*. 2013 Aug;22(4):537-42.
3. Elshof LE, Schmidt MK, Rutgers EJ, et al. Cause-specific Mortality in a Population-based Cohort of 9799 Women Treated for Ductal Carcinoma In Situ. *Ann Surg*. 2017 Apr 3. doi: 10.1097/SLA.0000000000002239. [Epub ahead of print]
4. Punglia RS, Jiang W, Lipsitz SR, et al. Clinical risk score to predict likelihood of recurrence after ductal carcinoma in situ treated with breast-conserving surgery. *Breast Cancer Res Treat*. 2017 Oct 28. doi: 10.1007/s10549-017-4553-5. [Epub ahead of print]

Fokalität

1. Meijnen P, Bartelink H. Multifocal ductal carcinoma in situ of the breast: A contraindication for breast-conserving treatment? *J Clin Oncol* 2007;25:5548–5549
2. Rakovitch E, Pignol JP, Hanna W, et al. Significance of multifocality in ductal carcinoma in situ: outcomes of women treated with breast-conserving therapy. *J Clin Oncol* 2007;25:5591–5596

(mod.) Van Nuys Prognose Index und MSKCC Nomogramm

1. Lagios MD, Page DL, Silverstein MJ. Prospective study of wide excision alone for ductal carcinoma in situ of the breast. *J Clin Oncol* 2006;24:3809-11
2. Rudloff U, Jacks LM, Goldberg JL, et al. Nomogram for predicting the risk of local recurrence after breast conserving surgery for ductal carcinoma in situ. *J Clin Oncol* 2010; 28(23): 3762-9
3. Van Zee KJ, Patil S. Validation of a nomogram for predicting risk of local recurrence for ductal carcinoma in situ. *J Clin Oncol* 2012; 30(25): 3143-4.
4. Sweldens C, Peeters S, van Limbergen E, et al. Öocal relapse after breast-conserving therapy for ductal carcinoma in situ:

- a European single-center experience and external validation of the Memorial Sloan-Kettering Cancer Center DCIS nomogram. *Cancer J* 2014; 20(1): 1-7.
5. Lei RY, Carter DL, Antell AG, et al. A Comparison of Predicted Ipsilateral Tumor Recurrence Risks in Patients With Ductal Carcinoma in Situ of the Breast After Breast-Conserving Surgery by Breast Radiation Oncologists, the Van Nuys Prognostic Index, the Memorial Sloan Kettering Cancer Center DCIS Nomogram, and the 12-Gene DCIS Score Assay. *Adv Radiat Oncol* 2020;6(2):100607.
 6. Grimm LJ, Rahbar H, Abdelmalak M, et al: Ductal Carcinoma in Situ: State-of-the-Art Review. *Radiology*. 2021 Dec 21;211839. doi: 10.1148/radiol.211839. Online ahead of print.
 7. Wärnberg F, Karlsson P, Holmberg E, et al: Prognostic Risk Assessment and Prediction of Radiotherapy Benefit for Women with Ductal Carcinoma In Situ (DCIS) of the Breast, in a Randomized Clinical Trial (SweDCIS). *Cancers* 2021, 13,6103

Palpables DCIS

Palpabel + COX-2+p16+Ki-67+

Palpabel + ER-, HER2, +Ki-67+

HER2-Überexpression

ER/PgR (positiv vs. negativ)

DCIS-Score

1. Solin LJ, Gray R, Baehner FL, et al. A multigene expression assay to predict local recurrence risk for ductal carcinoma in situ of the breast. *J Natl Cancer Inst*. 2013 May 15;105(10):701-10.
2. Sarah Patricia Cate, Alyssa Gillego, Manjeet Chadha, et al. Does the Oncotype DCIS score impact treatment decisions? *J Clin Oncol* 31, 2013 (suppl 26; abstr 91)
3. Rakovitch E, Nofech-Mozes S, Hanna W et al. A large prospectively-designed study of the DCIS score. Predicting recurrence risk after local excision for ductal carcinoma in situ patients with and without irradiation. *SABCS 2015*. S5-04
4. Wood WC, Alvarado M, Buchholz DJ, et al. The current clinical value of the DCIS Score. *Oncology (Williston Park)*. 2014 May;28 Suppl 2:C2, 1-8, C3.
5. O'Keefe TJ, Blair SL, Hosseini A et al. HER2-Overexpressing Ductal Carcinoma In Situ Associated with Increased Risk of Ipsilateral Invasive Recurrence, Receptor Discordance with Recurrence. *Cancer Prev Res (Phila)*. 2020 Sep;13(9):761-

772. doi: 10.1158/1940-6207.CAPR-20-0024.

6. Lazzeroni M, DeCensi A, Guerrieri-Gonzaga A et al. Prognostic and predictive value of cell cycle progression (CCP) score in ductal carcinoma in situ of the breast. *Mod Pathol.* 2020 Jun;33(6):1065-1077. doi: 10.1038/s41379-020-0452-0.
7. Hwang KT, Suh YJ, PARK CH, et al: Hormone Receptor Subtype in Ductal Carcinoma in Situ: Prognostic and Predictive Roles of the Progesterone Receptor. *The Oncologist* 2021;26:e1939–e1950

DCIS mit Mikroinvasion – Behandlung analog zum invasiven Karzinom

1. Eng-Wong J, JP Costantino et al. The Impact of Systemic Therapy Following Ductal Carcinoma In Situ. *J Natl Cancer Inst Monogr* 2010; 41: 200 – 203
2. Ryan R, Tawfik O, Jensen RA, Anant S. Current Approaches to Diagnosis and Treatment of Ductal Carcinoma In Situ and Future Directions. *Prog Mol Biol Transl Sci.* 2017;151:33-80.

Intrinsische Subgruppen (Luminal A,B, HER+, triple negativ)

1. Noh JM, Lee J, Choi DH, et al. HER-2 overexpression is not associated with increased ipsilateral breast tumor recurrence in DCIS treated with breast-conserving surgery followed by radiotherapy. *Breast.* 2013 Oct;22(5):894-7.
2. Solin LJ.: Management of Ductal Carcinoma In Situ (DCIS) of the Breast: Present Approaches and Future Directions. *Curr Oncol Rep.* 2019 Mar 5;21(4):33. doi: 10.1007/s11912-019-0777-3.
3. Visser LL, Groen EJ, van Leeuwen FE, et al.: Predictors of an Invasive Breast Cancer Recurrence after DCIS: A Systematic Review and Meta-analyses. *Cancer Epidemiol Biomarkers Prev.* 2019 May;28(5):835-845. doi: 10.1158/1055-9965.EPI-18-0976. Epub 2019 Apr 25.
4. Van Bockstal MR, Agahozo MC, Koppert LB, et al. A retrospective alternative for active surveillance trials for ductal carcinoma in situ of the breast. *Int J Cancer.* 2019 Apr 24. doi: 10.1002/ijc.32362. [Epub ahead of print]
5. Liu Y, Shou K, Li J, et al. Ductal Carcinoma In Situ of the Breast: Perspectives on Tumor Subtype and Treatment. *Biomed Res Int.* 2020; 2020: 7251431. Published online 2020 May 27. doi: 10.1155/2020/7251431

Familiäre Karzinombelastung, Menopausenstatus, BMI und Brustdichte

1. Alaeikhaneshir S, Engelhardt EG, van Duijnhoven FH, et al. The impact of patient characteristics and lifestyle factors on


the risk of an ipsilateral event after a primary DCIS: A systematic review. *Breast*. 2020 Apr; 50: 95–103. Published online 2020 Feb 19. doi: 10.1016/j.breast.2020.02.006

Kontralaterales Mammakarzinom

1. Giardiello D, Kramer I, Hoening MJ, et al. Contralateral breast cancer risk in patients with ductal carcinoma in situ and invasive breast cancer. *NPJ Breast Cancer*. 2020; 6: 60. Published online 2020 Nov 3. doi: 10.1038/s41523-020-00202-8

Molecular Subtyping

1. Nofech-Mozes S, Hanna W, Rakovitch E. Molecular Evaluation of Breast Ductal Carcinoma in Situ with Oncotype DX DCIS. *Am J Pathol*. 2018 Dec 31. pii: S0002-9440(18)30581-9
2. Lei RY, Carter DL, Antell AG, et al. A Comparison of Predicted Ipsilateral Tumor Recurrence Risks in Patients With Ductal Carcinoma in Situ of the Breast After Breast-Conserving Surgery by Breast Radiation Oncologists, the Van Nuys Prognostic Index, the Memorial Sloan Kettering Cancer Center DCIS Nomogram, and the 12-Gene DCIS Score Assay. *Adv Radiat Oncol* 2020;6(2):100607.
3. Wärnberg F, Karlsson P, Holmberg E, et al: Prognostic Risk Assessment and Prediction of Radiotherapy Benefit for Women with Ductal Carcinoma In Situ (DCIS) of the Breast, in a Randomized Clinical Trial (SweDCIS). *Cancers (Basel)*. 2021 Dec 3;13(23):6103. doi: 10.3390/cancers13236103.
4. Hahn E, Rodin D, Sutradhar R: Can Molecular Biomarkers Help Reduce the Overtreatment of DCIS? *Curr Oncol*. 2023 Jun 13;30(6):5795-5806. doi: 10.3390/curroncol30060433. PMID: 37366916.
5. Dabbs D, Mittal K, Heineman S: Analytical validation of the 7-gene biosignature for prediction of recurrence risk and radiation therapy benefit for breast ductal carcinoma in situ. *Front Oncol*. 2023 May 19;13:1069059. doi: 10.3389/fonc.2023.1069059. eCollection 2023. PMID: 37274253
6. Shah C, Bremer T, Cox C: The Clinical Utility of DCISionRT® on Radiation Therapy Decision Making in Patients with Ductal Carcinoma In Situ Following Breast-Conserving Surgery. *Ann Surg Oncol*. 2021 Oct;28(11):5974-5984. doi: 10.1245/s10434-021-09903-1. PMID: 33821346

 Prognostic Factors for an Ipsilateral Recurrence after DCIS II		LoE
<ul style="list-style-type: none"> ▪ Hereditary breast cancer risk ▪ Premenopausal at time of DCIS diagnosis ▪ High BMI ▪ High breast density ▪ Growth pattern (cribriform / solid versus „clinging“ / micro-papillary) ▪ Residual tumor-associated microcalcifications ▪ Architecture ▪ (modified) Van Nuys Prognostic Index/ mitotic rate ▪ Palpable DCIS ▪ ER-, HER2+, Ki-67+ ▪ Scores: DCIS, Oncotype DX Breast DCIS Score (12 genes); CCP (23 genes) ▪ MSKCC Nomogram ▪ DCISionRT ▪ Intrinsic subtypes (luminal A, B, HER2+, triple negative) ▪ DCIS compared to invasive carcinoma with higher risk of contralateral BC ▪ High number of TILs 		<p>2a</p> <p>2a</p> <p>2a</p> <p>2a</p> <p>2b</p> <p>2b</p> <p>2b</p> <p>2b</p> <p>2b</p> <p>2b</p> <p>2b</p> <p>2b</p> <p>2b</p> <p>2b</p> <p>2b</p> <p>2b</p> <p>2b</p> <p>2b</p> <p>2b</p> <p>2b</p> <p>2b</p>
<small>© AGO e. V. in der DGGG e.V. sowie in der DKG e.V. Guidelines Breast Version 2025.1E www.ago-online.de FORSCHEN LEHREN HEILEN</small>		
<small>See also chapter "Prognostic Faktoren"</small>		

1. Visser LL, Elshof LE, Schaapveld M et al. Clinicopathological Risk Factors for an Invasive Breast Cancer recurrence after Ductal Carcinoma In Situ-A Nested Case-Control Study. Clin Cancer Res. 2018 Aug 1;24(15):3593-3601.
2. Rakovitch E, Gray R, Baehner FL et al. Refined estimates of local recurrence risks by DCIS score adjusting for clinicopathological features: a combined analysis of ECOG-ACRIN E5194 and Ontario DCIS cohort studies. Breast Cancer Res Treat. 2018 Jun;169(2):359-369
3. Cutuli B: Ductal carcinoma in situ in 2019: Diagnosis, treatment, prognosis. Presse Med. 2019 Oct;48(10):1112-1122
4. Badve SS, Gökmen-Polar: Ductal carcinoma in situ of breast: update 2019. Pathology. 2019 Oct;51(6):563-569.
5. Van Bockstal MR, Agahozo MC, Koppert LB: A retrospective alternative for active surveillance trials for ductal carcinoma in situ of the breast. Int J Cancer. 2020 Mar 1;146(5):1189-1197
6. Solin LJ: Management of Ductal Carcinoma In Situ (DCIS) of the Breast: Present Approaches and Future Directions. Curr Oncol Rep. 2019 Mar 5;21(4):33
7. Giannakeas V, Sopik V, Narod SA. Association of a Diagnosis of Ductal Carcinoma In Situ With Death From Breast Cancer. JAMA Netw Open. 2020 Sep; 3(9): e2017124. Published online 2020 Sep 16. doi: 10.1001/jamanetworkopen.2020.17124
8. Groen EJ, Hudecek J, Mulder L, et al. Prognostic value of histopathological DCIS features in a large-scale international interrater reliability study. Breast Cancer Res Treat. 2020; 183(3): 759–770. Published online 2020 Jul 30. doi:

10.1007/s10549-020-05816-x

Diagnostische Methode

1. Park HS, Park S, Cho J, et al. Risk predictors of underestimation and the need for sentinel node biopsy in patients diagnosed with ductal carcinoma in situ by preoperative needle biopsy. *J Surg Oncol*. 2013 Mar;107(4):388-92. doi: 10.1002/jso.23273. Epub 2012 Sep 24.
2. Schulz S, Sinn P, Golatta M, et al. Prediction of underestimated invasiveness in patients with ductal carcinoma in situ of the breast on percutaneous biopsy as rationale for recommending concurrent sentinel lymph node biopsy. *Breast*. 2013 Aug;22(4):537-42.
3. Elshof LE, Schmidt MK, Rutgers EJ, et al. Cause-specific Mortality in a Population-based Cohort of 9799 Women Treated for Ductal Carcinoma In Situ. *Ann Surg*. 2017 Apr 3. doi: 10.1097/SLA.0000000000002239. [Epub ahead of print]
4. Punglia RS, Jiang W, Lipsitz SR, et al. Clinical risk score to predict likelihood of recurrence after ductal carcinoma in situ treated with breast-conserving surgery. *Breast Cancer Res Treat*. 2017 Oct 28. doi: 10.1007/s10549-017-4553-5. [Epub ahead of print]

Fokalität

1. Meijnen P, Bartelink H. Multifocal ductal carcinoma in situ of the breast: A contraindication for breast-conserving treatment? *J Clin Oncol* 2007;25:5548–5549
2. Rakovitch E, Pignol JP, Hanna W, et al. Significance of multifocality in ductal carcinoma in situ: outcomes of women treated with breast-conserving therapy. *J Clin Oncol* 2007;25:5591–5596

(mod.) Van Nuys Prognose Index, MSKCC Nomogramm und DCISonRT

1. Lagios MD, Page DL, Silverstein MJ. Prospective study of wide excision alone for ductal carcinoma in situ of the breast. *J Clin Oncol* 2006;24:3809-11
2. Rudloff U, Jacks LM, Goldberg JL, et al. Nomogram for predicting the risk of local recurrence after breast conserving surgery for ductal carcinoma in situ. *J Clin Oncol* 2010; 28(23): 3762-9
3. Van Zee KJ, Patil S. Validation of a nomogram for predicting risk of local recurrence for ductal carcinoma in situ. *J Clin Oncol* 2012; 30(25): 3143-4.
4. Sweldens C, Peeters S, van Limbergen E, et al. Öocal relapse after breast-conserving therapy for ductal carcinoma in

situ: a European single-center experience and external validation of the Memorial Sloan-Kettering Cancer Center DCIS nomogram. *Cancer J* 2014; 20(1): 1-7.

5. Lei RY, Carter DL, Antell AG, et al. A Comparison of Predicted Ipsilateral Tumor Recurrence Risks in Patients With Ductal Carcinoma in Situ of the Breast After Breast-Conserving Surgery by Breast Radiation Oncologists, the Van Nuys Prognostic Index, the Memorial Sloan Kettering Cancer Center DCIS Nomogram, and the 12-Gene DCIS Score Assay. *Adv Radiat Oncol* 2020;6(2):100607.
6. Grimm LJ, Rahbar H, Abdelmalak M, et al: Ductal Carcinoma in Situ: State-of-the-Art Review. *Radiology*. 2021 Dec 21;211839. doi: 10.1148/radiol.211839. Online ahead of print.
7. Wärnberg F, Karlsson P, Holmberg E, et al: Prognostic Risk Assessment and Prediction of Radiotherapy Benefit for Women with Ductal Carcinoma In Situ (DCIS) of the Breast, in a Randomized Clinical Trial (SweDCIS). *Cancers* 2021, 13,6103

Palpables DCIS

Palpabel + COX-2+p16+Ki-67+

Palpabel + ER-, HER2, +Ki-67+

HER2-Überexpression

ER/PgR (positiv vs. negativ)

DCIS-Score

1. Solin LJ, Gray R, Baehner FL, et al. A multigene expression assay to predict local recurrence risk for ductal carcinoma in situ of the breast. *J Natl Cancer Inst*. 2013 May 15;105(10):701-10.
2. Sarah Patricia Cate, Alyssa Gillego, Manjeet Chadha, et al. Does the Oncotype DCIS score impact treatment decisions? *J Clin Oncol* 31, 2013 (suppl 26; abstr 91)
3. Rakovitch E, Nofech-Mozes S, Hanna W et al. A large prospectively-designed study of the DCIS score. Predicting recurrence risk after local excision for ductal carcinoma in situ patients with and without irradiation. *SABCS 2015*. S5-04
4. Wood WC, Alvarado M, Buchholz DJ, et al. The current clinical value of the DCIS Score. *Oncology (Williston Park)*. 2014 May;28 Suppl 2:C2, 1-8, C3.
5. O'Keefe TJ, Blair SL, Hosseini A et al. HER2-Overexpressing Ductal Carcinoma In Situ Associated with Increased Risk of Ipsilateral Invasive Recurrence, Receptor Discordance with Recurrence. *Cancer Prev Res (Phila)*. 2020 Sep;13(9):761-

772. doi: 10.1158/1940-6207.CAPR-20-0024.

6. Lazzeroni M, DeCensi A, Guerrieri-Gonzaga A et al. Prognostic and predictive value of cell cycle progression (CCP) score in ductal carcinoma in situ of the breast. *Mod Pathol.* 2020 Jun;33(6):1065-1077. doi: 10.1038/s41379-020-0452-0.
7. Hwang KT, Suh YJ, PARK CH, et al: Hormone Receptor Subtype in Ductal Carcinoma in Situ: Prognostic and Predictive Roles of the Progesterone Receptor. *The Oncologist* 2021;26:e1939–e1950

DCISionRT:

1. Weinmann S, Leo MC, Francisco M, et al. Validation of a Ductal Carcinoma *In Situ* Biomarker Profile for Risk of Recurrence after Breast-Conserving Surgery with and without Radiotherapy. *Clin Cancer Res.* 2020 Aug 1;26(15):4054-4063.
2. Shah C, Bremer T, Cox C, The Clinical Utility of DCISionRT® on Radiation Therapy Decision Making in Patients with Ductal Carcinoma In Situ Following Breast-Conserving Surgery. *Ann Surg Oncol.* 2021 Oct;28(11):5974-5984.

DCIS mit Mikroinvasion – Behandlung analog zum invasiven Karzinom

1. Eng-Wong J, JP Costantino et al. The Impact of Systemic Therapy Following Ductal Carcinoma In Situ. *J Natl Cancer Inst Monogr* 2010; 41: 200 – 203
2. Ryan R, Tawfik O, Jensen RA, Anant S. Current Approaches to Diagnosis and Treatment of Ductal Carcinoma In Situ and Future Directions. *Prog Mol Biol Transl Sci.* 2017;151:33-80.

Intrinsische Subgruppen (Luminal A,B, HER+, triple negativ)

1. Noh JM, Lee J, Choi DH, et al. HER-2 overexpression is not associated with increased ipsilateral breast tumor recurrence in DCIS treated with breast-conserving surgery followed by radiotherapy. *Breast.* 2013 Oct;22(5):894-7.
2. Solin LJ.: Management of Ductal Carcinoma In Situ (DCIS) of the Breast: Present Approaches and Future Directions. *Curr Oncol Rep.* 2019 Mar 5;21(4):33. doi: 10.1007/s11912-019-0777-3.
3. Visser LL, Groen EJ, van Leeuwen FE, et al.: Predictors of an Invasive Breast Cancer Recurrence after DCIS: A Systematic Review and Meta-analyses. *Cancer Epidemiol Biomarkers Prev.* 2019 May;28(5):835-845. doi: 10.1158/1055-9965.EPI-18-0976. Epub 2019 Apr 25.
4. Van Bockstal MR, Agahozo MC, Koppert LB, van Deurzen CHM. A retrospective alternative for active surveillance trials

- for ductal carcinoma in situ of the breast. *Int J Cancer*. 2019 Apr 24. doi: 10.1002/ijc.32362. [Epub ahead of print]
5. Liu Y, Shou K, Li J, et al. Ductal Carcinoma In Situ of the Breast: Perspectives on Tumor Subtype and Treatment. *Biomed Res Int*. 2020; 2020: 7251431. Published online 2020 May 27. doi: 10.1155/2020/7251431

Familiäre Karzinombelastung, Menopausenstatus, BMI und Brustdichte

1. Alaeikhaneshir S, Engelhardt EG, van Duijnhoven FH, et al. The impact of patient characteristics and lifestyle factors on the risk of an ipsilateral event after a primary DCIS: A systematic review. *Breast*. 2020 Apr; 50: 95–103. Published online 2020 Feb 19. doi: 10.1016/j.breast.2020.02.006

Kontralaterales Mammakarzinom


1. Giardiello D, Kramer I, Hooning MJ, et al. Contralateral breast cancer risk in patients with ductal carcinoma in situ and invasive breast cancer. *NPJ Breast Cancer*. 2020; 6: 60. Published online 2020 Nov 3. doi: 10.1038/s41523-020-00202-8

Molecular Profile

1. Nofech-Mozes S, Hanna W, Rakovitch E. Molecular Evaluation of Breast Ductal Carcinoma in Situ with Oncotype DX DCIS. *Am J Pathol*. 2018 Dec 31. pii: S0002-9440(18)30581-9
2. Rakovitch E, Gray R, Baehner FL, et al: Refined estimates of local recurrence risks by DCIS score adjusting for clinico-pathological features: a combined analysis of ECOG-ACRIN E5194 and Ontario DCIS cohort studies. *Breast Cancer Res Treat*. 2018; 169(2):359-369
3. Schiza A, Thurfjell V, Stenmark Tullberg A; Tumour-infiltrating lymphocytes add prognostic information for patients with low-risk DCIS: findings from the SweDCIS randomised radiotherapy trial *Eur J Cancer*. 2022 Jun; 168:128-137
4. Wu SL, Yu X, Mao X, Jin F. Prognostic value of tumor-infiltrating lymphocytes in DCIS: a meta-analysis. *BMC Cancer*. 2022 Jul 18;22(1):782. doi: 10.1186/s12885-022-09883-9.
5. Hahn E, Rodin D, Sutradhar R: Can Molecular Biomarkers Help Reduce the Overtreatment of DCIS? *Curr Oncol*. 2023 Jun 13;30(6):5795-5806. doi: 10.3390/curroncol30060433. PMID: 37366916.
6. Dabbs D, Mittal K, Heineman S: Analytical validation of the 7-gene biosignature for prediction of recurrence risk and radiation therapy benefit for breast ductal carcinoma in situ. *Front Oncol*. 2023 May 19;13:1069059. doi:

10.3389/fonc.2023.1069059. eCollection 2023. PMID: 37274253

7. Shah C, Bremer T, Cox C: The Clinical Utility of DCISionRT® on Radiation Therapy Decision Making in Patients with Ductal Carcinoma In Situ Following Breast-Conserving Surgery. *Ann Surg Oncol.* 2021 Oct;28(11):5974-5984. doi: 10.1245/s10434-021-09903-1. PMID: 33821346




DCIS – Radiotherapy Statements

- Radiotherapy has no impact on survival LoE 1a
- Radiotherapy reduces the risk of ipsilateral (invasive and non invasive) recurrences by 50 % LoE 1a
- The number needed to treat (for ipsilateral breast recurrence) is 9 (over all risk groups).

1. Bagenal J, Roche N, Ross G, Kirby A, Dodwell D: Should patients with ductal carcinoma in situ be treated with adjuvant whole breast radiotherapy after breast conservation surgery? BMJ. 2018 May 17;361:k1410. doi: 10.1136/bmj.k1410. Review.
2. Lebeau A, Kühn T.: Updates in the treatment of ductal carcinoma in situ of the breast. Curr Opin Obstet Gynecol. 2016 Feb;28(1):49-58.
3. Mannu GS, Wang Z, Broggio J et al. Invasive breast cancer and breast cancer mortality after ductal carcinoma in situ in women attending for breast screening in England, 1988-2014: population based observational cohort study. BMJ. 2020 May 27;369:m1570. doi: 10.1136/bmj.m1570.
4. Weinmann S, Leo MC, Francisco M et al. Validation of a Ductal Carcinoma In Situ Biomarker Profile for Risk of Recurrence after Breast-Conserving Surgery with and without Radiotherapy. Clin Cancer Res. 2020 Aug 1;26(15):4054-4063. doi: 10.1158/1078-0432.CCR-19-1152. DCISionRT test, the DS was prognostic for the risk of later breast events for women diagnosed with DCIS, following BCS.
5. Yang L, Lu D, Lai Y et al. Prognostic Score-Based Stratification Analysis Reveals Universal Benefits of Radiotherapy on Lowering the Risk of Ipsilateral Breast Event for Ductal Carcinoma In Situ Patients with Different Risk Levels. Ann Surg Oncol. 2020 Aug 13. doi: 10.1245/s10434-020-09003-6.
6. McCormick B, Winter KA, Woodward W, et al: Randomized Phase III Trial Evaluating Radiation Following Surgical

Excision for Good-Risk Ductal Carcinoma In Situ: Long-Term Report From NRG Oncology/RTOG 9804. *J Clin Oncol*. 2021 Nov 10;39(32):3574-3582. doi: 10.1200/JCO.21.01083.



DCIS – Adjuvant Radiotherapy

Oxford

	LoE	GR	AGO
Radiotherapy after:			
▪ Breast conserving surgery (BCS)	1a	A	+
▪ Mastectomy	2b	B	--
Radiotherapy procedure:			
▪ Conventionally fractionated radiotherapy (50 Gy in 25 fract.)	1a	A	+
▪ Hypofractionated radiotherapy (40-42,5 Gy in 15-16 fract.)	1a	A	+
▪ Radiotherapy boost of the tumor bed	1b	B	+/-
▪ in case of risk factors* (absolute benefit 5-y-RFS 4 %, rate of fibrosis significant increased)	1b	B	+/-
▪ without risk factors	2b	B	-
▪ Partial breast irradiation [age ≥ 50y, DCIS ≤ 3 cm, G1-2, R0 (≥ 5 mm), unifocal / unicentric]	1b	B	+

Side effects and disadvantages must be weighed against risk reduction. Omitting radiotherapy implies elevated risk for local recurrence without effect for overall survival even in the subset of „good risk“ patients. Lack of level-1 evidence supporting the omission of adjuvant radiotherapy in selected low-risk cases: < 2.5 cm, low and intermediate nuclear grade, mammographically detected.

* < 50 years or ≥ 50 years and diagnosis based on symptoms, ≥ 15 mm, multifocality, palpable tumor, resection margins < 10 mm, G2 / 3, central necrosis, comedo type

Radiotherapie nach: Brusterhaltender Operation (BEO) (gesamte Brust, WBI)

1. EBCTCG Correa C et al. Overview of the randomized trials of radiotherapy in ductal carcinoma in situ of the breast. J Natl Cancer Inst Monogr. 2010 (41); 162 – 77
2. Abram Recht. Are the Randomized Trials of Radiation Therapy for Ductal Carcinoma in Situ Still Relevant? J Clin Oncol 2014; 32(22): 3588
3. Lawrence J. Solin, Robert Gray, Lorie L. Hughes et al. Surgical Excision Without Radiation for Ductal Carcinoma in Situ of the Breast: 12-Year Results From the ECOG-ACRIN E5194 Study. J Clin Oncol 2015; 33 (33):3938
4. Beryl McCormick, Kathryn Winter, Clifford Hudis, et al. RTOG 9804: A Prospective Randomized Trial for Good-Risk Ductal Carcinoma In Situ Comparing Radiotherapy With Observation. J Clin Oncol 2015; 33(7): 709
5. Garg PK, Jakhetiya A, Pandey R, et al. Adjuvant radiotherapy versus observation following lumpectomy in ductal carcinoma in-situ: A meta-analysis of randomized controlled trials. Breast J. 2017 Aug 22. doi: 10.1111/tbj.12889. [Epub ahead of print]
6. Giannakeas V, Sopik V, Narod SA. Association of Radiotherapy With Survival in Women Treated for Ductal Carcinoma In Situ With Lumpectomy or Mastectomy. JAMA Netw Open. 2018 Aug 3;1(4):e181100.
7. Offersen BV, Alsner J, Nielsen HM et al. Hypofractionated Versus Standard Fractionated Radiotherapy in Patients With Early Breast Cancer or Ductal Carcinoma In Situ in a Randomized Phase III Trial: The DBCG HYPO Trial. Danish Breast

- Cancer Group Radiation Therapy Committee. J Clin Oncol. 2020 Nov 1;38(31):3615-3625. doi: 10.1200/JCO.20.01363.
8. Olivotto IA, Link E, Phillips C et al. International comparison of cosmetic outcomes of breast conserving surgery and radiation therapy for women with ductal carcinoma in situ of the breast. BIG 03-07/TROG 07.01 trial investigators. Radiother Oncol. 2020 Jan;142:180-185. doi: 10.1016/j.radonc.2019.07.024.
 9. Yang L, Lu D, Lai Y et al. Prognostic Score-Based Stratification Analysis Reveals Universal Benefits of Radiotherapy on Lowering the Risk of Ipsilateral Breast Event for Ductal Carcinoma In Situ Patients with Different Risk Levels. Ann Surg Oncol. 2020 Aug 13. doi: 10.1245/s10434-020-09003-6.
 10. King MT, Link EK, Whelan TJ et al. BIG 3-07/TROG 07.01 trial investigators. Quality of life after breast-conserving therapy and adjuvant radiotherapy for non-low-risk ductal carcinoma in situ (BIG 3-07/TROG 07.01): 2-year results of a randomised, controlled, phase 3 trial. Lancet Oncol. 2020 May;21(5):685-698. doi: 10.1016/S1470-2045(20)30085-1.

Boost

1. Chua BH, Link EK, Kunkler IH, Lancet 2022 Aug 6; 400(10350):431-440, Radiation doses and fractionation schedules in non-low-risk ductal carcinoma in situ in the breast (BIG 3-07/TROG 07.01): a randomized, factorial , multicentre, open-label, phase 3 study.

Mastektomie

1. Chadha M, Portenoy J, Boolbol SK, et al. Is there a role for postmastectomy radiation therapy in ductal carcinoma in situ? Int J Surg Oncol 2012;2012:423520. doi: 10.1155/2012/423520. Epub 2012 Jun 13.


Teilbrustbestrahlung

1. Whelan TJ, Julian JA, Berrang TS: External beam accelerated partial breast irradiation versus whole breast irradiation after breast conserving surgery in women with ductal carcinoma in situ and node-negative breast cancer (RAPID): a randomised controlled trial. Lancet. 2019 Dec 14;394(10215):2165-2172. doi: 10.1016/S0140-6736(19)32515-2.
2. Vicini FA, Cecchini RS, White JR et al.: Long-term primary results of accelerated partial breast irradiation after breast-conserving surgery for early-stage breast cancer: a randomised, phase 3, equivalence trial. Lancet. 2019 Dec 14;394(10215):2155-2164
3. Strnad V, Krug D, Sedlmayer F, et al. Breast Cancer Expert Panel of the German Society of Radiation Oncology (DEGRO).

DEGRO practical guideline for partial-breast irradiation. *Strahlenther Onkol.* 2020; 196(9): 749–763. Published online 2020 Apr 29. doi: 10.1007/s00066-020-01613-z

Intraoperative Strahlentherapie beim DCIS

1. Banks A, Coronado G, Zimmerman R et al. Breast conserving surgery with targeted intraoperative radiotherapy for the management of ductal carcinoma in situ. *J Surg Oncol.* 2018 Dec 27. doi: 10.1002/jso.25347. [Epub ahead of print]




DCIS – Adjuvant Systemic Treatment

- **Adjuvant endocrine treatment has no impact on survival (RR 1.11; 95% CI 0.89-1.39)** LoE 1a
 - **Endocrine treatment may have a small effect on ipsilateral invasive (HR 0.79; 95% CI 0.62-1.01) and DCIS (HR 0.75; 95% CI 0.61-0.92) recurrences** LoE 1a
 - **Endocrine treatment have a substantial effect on invasive recurrence if no radiotherapy after breast conserving surgery (HR=0.49, 95% CI: 0.28, 0.84)** LoE 2
 - **Endocrine treatment for DCIS has an effect on contralateral invasive (RR 0.57; 95% CI 0.39-0.83) and non-invasive (RR 0.50; 95% CI 0.28-0.87) cancer** LoE 1a
 - **The number needed to treat for any ipsilateral breast event is 15** LoE 1a
 - **The number needed to treat to prevent invasive breast cancer is 29 for anastrozole vs. 59 for tamoxifen*** LoE 1b
- * within 12 years; according to IBIS II-trial

1. El Hage Chehade H, Mokbel K. Is Adjuvant Endocrine Therapy Indicated for DCIS Patients After Complete Surgical Excision? *Anticancer Res.* 2018 Mar;38(3):1263-1266.
2. Johnston SR: Endocrine treatment for ductal carcinoma in situ: balancing risks and benefits. *Lancet.* 2016 Feb 27;387(10021):819-21.
3. Altundag K: Is it rational to extend the duration of preventive endocrine treatment in hormone receptor positive ductal carcinoma in situ? *J BUON.* 2018 May-Jun;23(3):835.
4. Cuzick J, Sestak I, Forbes JF et al. Use of anastrozole for breast cancer prevention (IBIS-II): long-term results of a randomised controlled trial. *Lancet.* 2020 Jan 11;395(10218):117-122. doi: 10.1016/S0140-6736(19)32955-1.
5. Hwang KT , Suh YJ, PARK CH, et al: Hormone Receptor Subtype in Ductal Carcinoma in Situ: Prognostic and Predictive Roles of the Progesterone Receptor. *The Oncologist* 2021;26:e1939–e1950
6. Staley H, McCallum I, BruceJ: Postoperative Tamoxifen for ductal carcinoma in situ: Cochrane systematic review and meta-analysis. *Breast* 2014 Oct;23(5):546-51, doi: 10.1016/j.breast.2014.06.015.
7. Yanli Yan, Long Zhang, Li Tan: Endocrine Therapy for Ductal Carcinoma In Situ (DCIS) of the Breast with Breast Conserving Surgery (BCS) and Radiotherapy (RT): a Meta-Analysis. *Pathol Oncol Res* 2020 Jan;26(1):521-531. doi: 10.1007/s12253-018-0553-y.
8. Wright J et al.: Impact of Tamoxifen Only after Breast Conservation Surgery for 'Good Risk' Duct Carcinoma in Situ:

Results from the NRG Oncology/RTOG 9804 and ECOG-ACRIN E5194 Trial SABCS 2024 GS2-02



DCIS – Adjuvant Systemic Treatment

	Oxford		
	LoE	GR	AGO
▪ Tamoxifen (only ER+) 20 mg	1a	A	+/-*
▪ Tamoxifen (only ER+) 5 mg for 3 years	2b	B	+/-*
▪ Aromatase inhibitor (only ER+) in postmenopausal women only	1b	A	+/-**
▪ Trastuzumab (only HER2+)	5	D	--

* Indication for treatment depends on risk factors, RT use, side effects and patient preference

Anastrozole versus Tamoxifen: Anastrozole higher fracture rate (OR 1.34), Tamoxifen higher rate of stroke (OR 3.10) and TIA (OR 3.10)

Tamoxifen (nur ER+, nur BET)

1. Fisher B, Dignam J, Wolmark N, et al. Tamoxifen in treatment of intraductal breast cancer: National Surgical Adjuvant Breast and Bowel Project B-24 randomised controlled trial. *Lancet*. 1999 Jun 12;353(9169):1993-2000.
2. Cuzick J, I Sestak et al. (2010): "Effect of Tamoxifen and radiotherapy in women with locally excised ductal carcinoma in situ: long-term results form the UK / ANZ DCIS trial" *Lancet Oncol* (12) 21- 29
3. Wapnir IL, Dignam JJ, Fisher B, et al. Long-Term Outcomes of invasive ipsilateral breast tumor recurrences after lumpectomy in NSABP B-17 and B-24 randomized clinical trials for DCIS. *J Natl Cancer Inst* 2011; 103: 478-488
4. Staley H, McCallum I, Bruce J. Postoperative Tamoxifen for ductal carcinoma in situ: Cochrane systematic review and meta-analysis. *Breast*. 2014 Oct;23(5):546-51. doi: 10.1016/j.breast.2014.06.015. Epub 2014 Jul 9
5. El Hage Chehade H, Mokbel K. Is Adjuvant Endocrine Therapy Indicated for DCIS Patients After Complete Surgical Excision? *Anticancer Res*. 2018 Mar;38(3):1263-1266.
6. Johnston SR: Endocrine treatment for ductal carcinoma in situ: balancing risks and benefits. *Lancet*. 2016 Feb 27;387(10021):819-21.
7. Altundag K: Is it rational to extend the duration of preventive endocrine treatment in hormone receptor positive ductal carcinoma in situ? *J BUON*. 2018 May-Jun;23(3):835.
8. Lazzeroni, M, Puntoni, M, 2, Aliana Guerrieri-Gonzaga, A: Randomized Placebo Controlled Trial of Low-Dose Tamoxifen


to Prevent Recurrence in Breast Noninvasive Neoplasia: A 10-Year Follow-Up of TAM-01 Study. *J Clin Oncol*. 2023 Jun 10;41(17):3116-3121.

AI (wenn postmenopausal)

1. Richard G Margolese, Reena S Cecchini, Thomas B Julian, et al. Anastrozole versus tamoxifen in postmenopausal women with ductal carcinoma in situ undergoing lumpectomy plus radiotherapy (NSABP B-35): a randomised, double-blind, phase 3 clinical trial. www.thelancet.com Published online December 10, 2015
2. Patricia A Ganz, Reena S Cecchini, Thomas B Julian, et al. Patient-reported outcomes with anastrozole versus tamoxifen for postmenopausal patients with ductal carcinoma in situ treated with lumpectomy plus radiotherapy (NSABP B-35): a randomised, double-blind, phase 3 clinical trial. www.thelancet.com Published online December 10, 2015
3. John F Forbes, Ivana Sestak, Anthony Howell, et al. Anastrozole versus tamoxifen for the prevention of locoregional and contralateral breast cancer in postmenopausal women with locally excised ductal carcinoma in situ (IBIS-II DCIS): a double-blind, randomized controlled trial. www.thelancet.com Published online December 11, 2015.
4. Wang L, Xia Y, Liu D, et al. Evaluating the efficacy of post-surgery adjuvant therapies used for ductal carcinoma (ca. in situ) patients: a network meta-analysis. *Oncotarget*. 2017;8(45):79257-79269.

AI vs. Tamoxifen

1. Cuzick J, Sestak I, Forbes JF et al. Use of anastrozole for breast cancer prevention (IBIS-II): long-term results of a randomised controlled trial. *Lancet*. 2020 Jan 11;395(10218):117-122. doi: 10.1016/S0140-6736(19)32955-1.
2. Yan Y, Zhang L, Tan L et al. Endocrine Therapy for Ductal Carcinoma In Situ (DCIS) of the Breast with Breast Conserving Surgery (BCS) and Radiotherapy (RT): a Meta-Analysis. *Pathol Oncol Res*. 2020 Jan;26(1):521-531. doi: 10.1007/s12253-018-0553-y.
3. Sestak I, Cuzick J, Bonanni B, et al. Updates long-term results of anastrozole versus tamoxifen for the prevention of breast cancer in postmenopausal women with locally excised ductal carcinoma In-situ (IBIS-II DCIS). *SABCS*, 2020



© AGO e. V.
in der DGGG e.V.
sowie
in der DKG e.V.

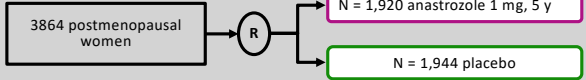
Guidelines Breast
Version 2025.1E

www.ago-online.de

FORSCHEN
LEHREN
HEILEN

Use of Anastrozole for Breast Cancer Prevention (IBIS-II): Long-Term Results of a Randomised Controlled Trial

Cuzick J et al, Lancet 2020




```


graph LR
    A[3864 postmenopausal women] --> B((R))
    B --> C[N = 1,920 anastrozole 1 mg, 5 y]
    B --> D[N = 1,944 placebo]
  
```

- N = 3,864 postmenopausal women at increased risk for breast cancer,
- median follow-up of 131 months,
- results:
 - 49% reduction of all breast cancers with anastrozole (HR 0.51, 95% CI 0.39–0.66, p < 0.0001),
 - significant reduction in incidence for anastrozole for ductal carcinoma in situ (HR 0.41, 0.22–0.79, p = 0.0081), especially for oestrogen-positive (HR 0.22, 0.07–0.65, p = 0.0062),
 - 5-year adherence anastrozole 74.6% vs. 77.0% for placebo,
 - no difference in major side effects (fractures, myocardial infarctions, deep vein thrombosis, pulmonary embolism),
 - NNT to prevent one breast cancer during 12 years: 29 (anastrozole) vs. 59 (tamoxifen).

1. Cuzick J, Sestak I, Forbes JF et al. Use of anastrozole for breast cancer prevention (IBIS-II): long-term results of a randomised controlled trial. Lancet. 2020 Jan 11;395(10218):117-122. doi: 10.1016/S0140-6736(19)32955-1.
2. Cuzick J, Sestak I, Cawthorn S, et al. Tamoxifen for prevention of breast cancer: extended long-term follow-up of the IBIS-I breast cancer prevention trial. Lancet Oncol 2015; 16: 67–75.



ARBEITSGEMEINSCHAFT
STRAHLTHERAPEUTISCHE
ONKOLOGIE E.V.



MAMMA

© AGO e. V.
in der DGGG e.V.
sowie
in der DKG e.V.

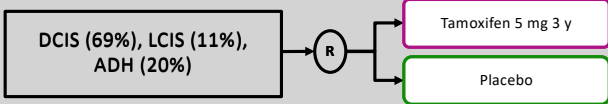
Guidelines Breast
Version 2025.1E

www.ago-online.de

FORSCHEN
LEHREN
HEILEN

Low Dose Tamoxifen (5 mg) in Premalignant Lesions

Lazzeroni M et al: J Clin Oncol 2023



- **N = 500,**
- **follow-up 9.7 years,**
- **results:**
 - Events: 66 breast cancers (15 in situ; 51 invasive) were diagnosed: Tam 25 and Placebo 41; hazard ratio: 0.58; 95% CI, 0.35 to 0.95; log-rank $P = .03$.
 - Contralateral BC incidence: Tam 6 vs. Plac 16 (HR, 0.36; 95% CI, 0.14 - 0.92; $P = .025$)
 - NNT to prevent one case of breast event with tam 22 in 5 and 14 in 10 years.
 - Severe adverse event: no significant differences
 - Adherence Tam 65% vs. PLAC 61%.

1. Lazzeroni M, Puntoni M, Provinciali N et al.: Estimating the magnitude of clinical benefit of systemic therapy in patients with DCIS or pre-invasive disease of the breast. Breast. 2019 Nov;48 Suppl 1:S39-S43.
2. DeCensi A, Puntoni M, Guerrieri-Gonzaga A: Randomized Placebo Controlled Trial of Low-Dose Tamoxifen to Prevent Local and Contralateral Recurrence in Breast Intraepithelial Neoplasia. J Clin Oncol. 2019 Jul 1;37(19):1629-1637.
3. Lazzeroni, M, Puntoni, M, 2, Aliana Guerrieri-Gonzaga, A: Randomized Placebo Controlled Trial of Low-Dose Tamoxifen to Prevent Recurrence in Breast Noninvasive Neoplasia: A 10-Year Follow-Up of TAM-01 Study. J Clin Oncol. 2023 Jun 10;41(17):3116-3121.

Therapy of Local intramammary DCIS Recurrence after Tumorectomy

	Oxford		
	LoE	GR	AGO
After Radiation:			
▪ Simple mastectomy	3a	C	+
+ SLNE (if no previous axillary staging)	5	D	+
▪ Secondary breast conserving surgery	4	C	+/-
▪ Re-irradiation as partial breast irradiation*	2b	C	+/-
Without radiation after first tumorectomy			
▪ Treatment like primary disease	3	C	++

* A preoperative consultation with a radiation oncologist to evaluate if partial breast irradiation is an option is recommended.

1. Li Q, Wang K, Yang L: Long-term Survival Comparison of Repeated Breast-conserving Surgery Versus Mastectomy for Patients with DCIS with Ipsilateral Breast Tumor Recurrence: A Real-world Longitudinal Study. 2021 Aug;21(4):360-372. doi: 10.1016/j.clbc.2021.02.012.
2. Arthur DW, Winter KA, Kuerer HM. Effectiveness of Breast Conserving Surgery and 3-D Conformal Partial Breast Reirradiation for Recurrence of Breast Cancer in the ipsilateral Breast. The NRG Oncology/RTOG 1014 Phase 2 Clinical Trial. JAMA Oncol 2020;6 (1):75-82

Nach Radiatio

Einfache Mastektomie

+ SN B

1. Silverstein MJ, MD Lagios et al (1998): "Outcome After Invasive Local Recurrence in Patients With Ductal Carcinoma In Situ of the Breast" J Clin Oncol 16:1367-1373

Sekundäre Tumorektomie führt zu Rezidiven in bis zu 30 % der Fälle (NSABP B17)

1. Fisher ER, Dignam J, Tan-Chiu E et al. (1999): "Pathologic findings from the National Surgical Adjuvant Breast Project (NSABP) eight-year update of Protocol B-17: intraductal carcinoma" Cancer 86: 429–438