



Diagnosis and Treatment of Patients with early and advanced Breast Cancer

© AGO e. V.
in der DGGG e.V.
sowie
in der DKG e.V.

Guidelines Breast
Version 2019.1

Lesions of Uncertain Malignant Potential (B3)

(ADH, LIN, FEA, Papilloma, Radial Scar)

Lesions of Uncertain Malignant Potential (B3) (including “Precursor Lesions”)

- **Versions 2005–2018:**

**Albert / Audretsch / Brunnert / Fersis / Friedrich /
Friederichs / Gerber / Kreipe / Nitz / Rody / Schreer /
Sinn / Thomssen / Huober / Kreipe / Friedrich / Sinn**

- **Version 2019:**

Ditsch / Kreipe



© AGO e. V.
in der DGGG e.V.
sowie
in der DKG e.V.

Guidelines Breast
Version 2019.1

www.ago-online.de

**FORSCHEN
LEHREN
HEILEN**

Pathology Reporting for Minimal Invasive Biopsies

B-Classification*

- B1 = unsatisfactory or normal tissue only**
- B2 = benign lesion**
- B3 = lesion of uncertain malignant potential**
- B4 = suspicion of malignancy**
- B5 = malignant**
 - B5a = non-invasive**
 - B5b = invasive**
 - B5c = in situ/invasion not assessable**
 - B5d = non epithelial, metastatic**

* National Coordinating Group for Breast Screening Pathology (NHSBSP),
E.C. Working Group on Breast Screening Pathology, S3-Leitlinie Mammakarzinom der DKG

B3-Lesions

© AGO e. V.
in der DGGG e.V.
sowie
in der DKG e.V.

Guidelines Breast
Version 2019.1

1. Lesions with increased risk of associated DCIS or invasive carcinoma

- Atypical ductal hyperplasia (ADH) or atypical epithelial proliferation of ductal type (classification possibly as B4, depending on extent of lesion)
- Flat epithelial atypia (FEA)
- Lobular neoplasia (LIN; LN; now subdivided into ALH and LCIS, no differentiation according to older nomenclature) classical and non-classical type
- Atypical apocrine adenosis

2. Potentially heterogeneous lesions with risk of incomplete sampling

- Cellular fibroepithelial lesion or phyllodes tumour without evidence of malignancy
- Intraductal papilloma with/without atypia (possibly also B4, depending on the extent of the lesion)
- Radial scar or complex sclerosing lesion (unless the radial scar only microscopically, not radiologically detected: B2)
- Hemangioma

3. Rare Lesions

- Adenomyoepithelioma, microglandular adenosis, mucocele-like lesion, nodular fasciitis, desmoid-type fibromatosis, spindle cell lesion of unknown significance

Main types of B3-Lesions and Prospective Predictive Value (PPV) of Malignancy in Resection Specimen (DCIS/inv. Ca.)



© AGO e. V.
in der DGGO e.V.
sowie
in der DKG e.V.

Guidelines Breast
Version 2019.1

B3-Lesions:

| | ~PPV |
|--|---------|
| ▪ Atypical ductal hyperplasia (ADH) | 20–30 % |
| ▪ Lobular intraepithelial neoplasia (LN/LIN) | 0–10 % |
| ▪ Flat epithelial atypia (FEA) | 0–10 % |
| ▪ Radial scar / Complex sclerosing lesion | 0–10 % |
| ▪ Papilloma without atypia | 0–10 % |
| ▪ Cellular fibroepithelial tumors / phyllodes tumors | 0% |

www.ago-online.de

FORSCHEN
LEHREN
HEILEN

Management after Minimally Invasive Biopsy



© AGO e. V.
in der DGGG e.V.
sowie
in der DKG e.V.

Guidelines Breast
Version 2019.1

- **Interdisciplinary conference:
Concordant findings in pathology and imaging?**

→ **yes: proceed according to histologic type**

→ **no: open biopsy**

Vacuum-assisted biopsy (after core biopsy)

| Oxford | | |
|--------|----|-----|
| LoE | GR | AGO |

| | | |
|----|---|----|
| 3a | C | ++ |
| 3a | C | ++ |
| 5 | D | + |

Atypical ductal Hyperplasia (ADH)

© AGO e. V.
in der DGGG e.V.
sowie
in der DKG e.V.

Guidelines Breast
Version 2019.1

- **Synonyms:** Atypical intraductal epithelial proliferation (AIDEP), atypical epithelial proliferation of ductal type
- **Definition:** Atypical intraductal proliferations with cytological and structural features of well differentiated DCIS, such as rigid bridging or micropapillae, well demarcated cell borders and occupy less than two separate duct spaces. The extension of all involved lumens within one ductulo-lobular unit is less than 2 mm. Atypical ductal proliferations larger than 2 mm or in at least two ductules are classified as DCIS (low-grade).
- **Indicator/Precursor lesion:** Ipsi- and contralateral breast cancer risk: RR 3 - 5 x after 3 - 5 years.
- Particularly high risk for breast cancer when combined with BIRADS IV / V and high breast volume.

Strategy after Diagnosis of ADH in Biopsy Specimen

| | Oxford | | |
|--|--------|----|-----|
| | LoE | GR | AGO |

ADH in core- / vacuum-assisted biopsy:

- Open excisional biopsy
- Open excisional biopsy may be omitted, with:
 - a) No mass-lesion radiologically, and
 - b) a small lesion (≤ 2 TDLU*) in vacuum biopsy, and
 - c) complete removal of imaging abnormality

| | | |
|----|---|----|
| 3a | C | ++ |
|----|---|----|

| | | |
|----|---|-----|
| 5a | C | +/- |
|----|---|-----|

ADH at margins in open biopsy specimen:

- No further surgery, if incidental finding accompanies invasive or intraductal carcinoma

| | | |
|----|---|----|
| 3a | C | ++ |
|----|---|----|

* Terminal ductal-lobular unit

Risk of Breast Cancer after Atypical Hyperplasy (ADH, ALH)



Stratification of breast cancer risk*

| | | |
|---|-------------|------------------------|
| <ul style="list-style-type: none"> Number of Foci: | 1 | RR = 2.65 (2.06–3.41) |
| | 2 | RR = 5.19 (3.59–7.52) |
| | ≥ 3 | RR = 8.94 (5.48–14.59) |
| <ul style="list-style-type: none"> Microcalcifications | present | RR = 3,21 |
| | not present | RR = 4,21 |
| <ul style="list-style-type: none"> Type | ductal | RR = 3,83 |
| | lobular | RR = 3,67 |
| | both | RR = 7,10 |
| <ul style="list-style-type: none"> Age | < 45 | RR = 6,76 |
| | 45–55 | RR = 5,10 |
| | > 55 | RR = 2,67 |

© AGO e. V.
in der DGGG e.V.
sowie
in der DKG e.V.

Guidelines Breast
Version 2019.1

www.ago-online.de

FORSCHEN
LEHREN
HEILEN

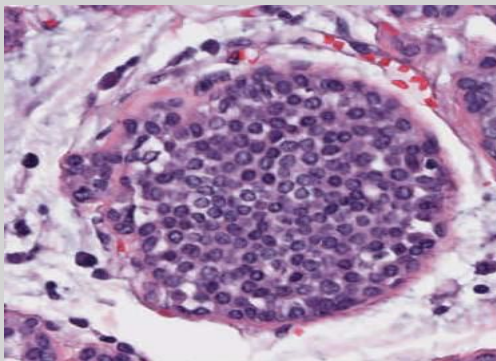
Lobular Intraepithelial Neoplasia (LIN)

- Includes: Atypical lobular hyperplasia, lobular carcinoma in situ, LCIS/CLIS
- LIN 1–3 classification is not sufficiently validated prognostically
- Pleomorphic LIN and LIN with comedo-type necrosis are classified as premalignant → **B5a**
- Indicator/Precursor lesion:
Ipsi- and contralaterally increased breast cancer risk:
7 x after 10 years

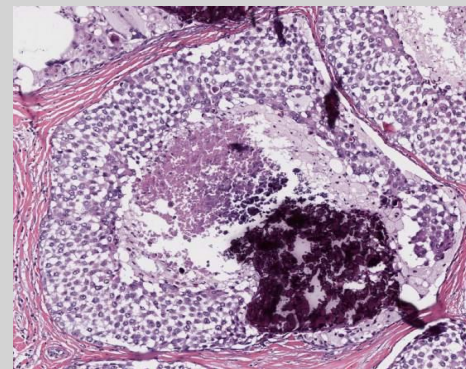
Classical LIN and Variants of LIN with increased risk

© AGO e. V.
in der DGGG e.V.
sowie
in der DKG e.V.

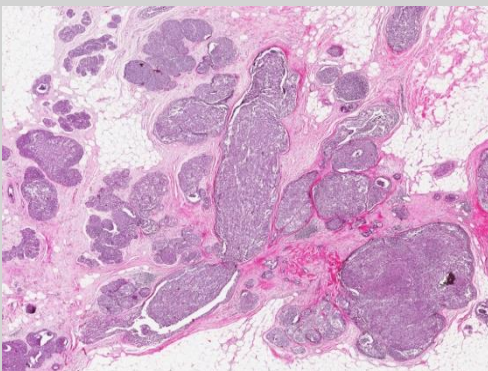
Guidelines Breast
Version 2019.1



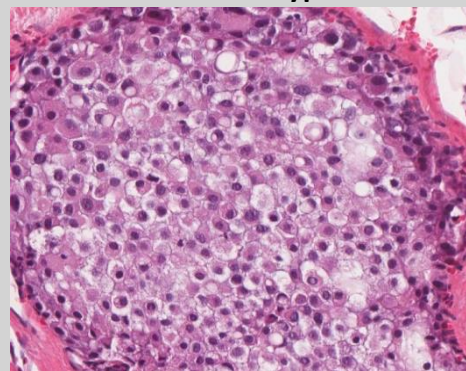
Classical LIN



LIN with comedo type necrosis



Florid LIN



Pleomorphic LIN

LIN with High Risk

© AGO e. V.
in der DGGG e.V.
sowie
in der DKG e.V.

Guidelines Breast
Version 2019.1

- **Pleomorphic LCIS: high grade cellular atypia, frequent involvement of ductules, comedo-type necrosis, microcalcifications**
- **Florid LCIS: Involvement of numerous lobuli with distension and near confluence, extension to ductules and neighbouring TDLU**
- **Type of LCIS with 21 cases of LCIS with microinvasion*:**
 - **classical LCIS: n = 11**
 - **florid LCIS: n = 4**
 - **pleomorphic LCIS: n = 1**

Strategy after Diagnosis of LIN

© AGO e. V.
in der DGGG e.V.
sowie
in der DKG e.V.

Guidelines Breast
Version 2019.1

| | Oxford | | |
|--|--------|----|-----|
| | LoE | GR | AGO |
| <ul style="list-style-type: none"> <u>LIN in core- / vacuum-assisted biopsy:</u> <ul style="list-style-type: none"> → No further studies when LIN (classical variant) represents an incidental or isolated finding in core or vacuum biopsy and concordance in imaging → Open excisional biopsy, with pleomorphic LIN, florid LIN, or LIN with comedo type necrosis or when not concordant with imaging findings | 2b | C | ++ |
| <ul style="list-style-type: none"> <u>LIN at margins of resection specimen (BCT):</u> <ul style="list-style-type: none"> → No further surgery | 2a | C | ++ |
| <ul style="list-style-type: none"> <u>Exceptions:</u> <ol style="list-style-type: none"> Pleomorphic LIN, florid LIN, or LIN with necrosis Imaging abnormality is not removed | | | |

Flat Epithelial Atypia (FEA)

© AGO e. V.
in der DGGG e.V.
sowie
in der DKG e.V.

Guidelines Breast
Version 2019.1

- **Synonyms:** Columnar cell hyperplasia with atypia, columnar cell metaplasia with atypia, ductal intraepithelial neoplasia grade 1A (DIN 1A)
- **Differential diagnosis:**
 - ADH is discriminated by architectural features (micropapillary, cribriform) → **B3**
 - Clinging carcinoma is discriminated by high grade nuclear atypia (G2/G3) and classified as ductal carcinoma in situ → **B5a**
- **Marker lesion:**

FEA frequently is associated with calcifications and may be associated with low-grade intraductal carcinoma. Frequent occurrence in combination with high density of the breast (OR1.3). High risk for associated breast cancer in the presence of extensive calcifications (also when 75% of calcification remained after biopsy), age > = 57J, > 1 cm in imaging, > = 4 foci.

Strategy after Diagnosis of FEA

| Oxford | | |
|--------|----|-----|
| LoE | GR | AGO |

- **FEA in core biopsy/vacuum-assisted biopsy:**

- Open excisional biopsy may be omitted under the following circumstances:

- a) a small lesion (≤ 2 TDLU* in vacuum biopsy)
 - and**

- b) Complete or near complete removal of imaging abnormality

- Representative open excisional biopsy in radiologically extensive microcalcifications or discordance to the radiological result

- **FEA at margins in resection specimen:**

- No further surgery, unless calcifications have not been completely removed

| | | |
|----|---|---|
| 3b | C | + |
|----|---|---|

| | | |
|---|---|---|
| 5 | C | + |
|---|---|---|

| | | |
|----|---|----|
| 3b | C | ++ |
|----|---|----|

* Terminal ductal-lobular unit

Papilloma

© AGO e. V.
in der DGGG e.V.
sowie
in der DKG e.V.

Guidelines Breast
Version 2019.1

- **Includes:** Central and peripheral papilloma > 2 mm, atypical intraductal papilloma (B3)
- To be **distinguished from** peripheral micropapilloma arising in the TDLU, size ≤ 2 mm, may be multiple
- To be distinguished from papilloma with DCIS, from intraductal papillary carcinoma, and from encapsulated papillary carcinoma
- **Indicator lesion:**
May be associated with in-situ or invasive cancer (up to 6% without atypia if concordant imaging, up to 30% with atypia), increased ipsilateral risk for cancer (up to 4.6% and up to 13% in case of atypical papilloma) .

Strategy after Diagnosis of Papilloma

| Oxford | | |
|--------|----|-----|
| LoE | GR | AGO |

- **Papilloma without atypia in core needle or vacuum biopsy:**
 - no further therapy, when biopsy sufficiently representative (100 mm²) and no discordance to imaging
- **Multiple papillomas**
 - open biopsy
- **Papilloma with atypia in core needle or vacuum biopsies:**
 - open biopsy
- **Papilloma at resection margin:**
 - no published data available

3a C ++

3a C ++

3a C ++

Radially Sclerosing Lesion

©AGO e. V.
in der DGGG e.V.
sowie
in der DKG e.V.

Guidelines Breast
Version 2019.1

- **Benign pseudoinfiltrative lesion with central fibroelastic core and radial configuration.**
- **Includes:**
 - radial scar
 - complex sclerosing lesion (> 1 cm)
- **Additional risk factor in patients with benign epithelial hyperplasia (proliferating breast disease)**
- **Risk for upgrade in open biopsy after diagnosis of a radial sclerosing lesion, depending on the size of the needle (CNB) or method (VAB) and additional atypia: 1–18%**

Strategy after Diagnosis of Radial Scar, Complex Sclerosing Lesion (CSL)

| Oxford | | |
|--------|----|-----|
| LoE | GR | AGO |

- **Radial scar / CSL in core- / vacuum-assisted biopsy:**

- Open excisional biopsy may be omitted with a small (< 5mm) lesion or complete removal or near complete removal of imaging abnormality

| | | |
|----|---|---|
| 5a | C | + |
|----|---|---|

- **Radial scar / CSL at margins in resection specimen:**

- No further surgery

| | | |
|----|---|----|
| 3b | C | ++ |
|----|---|----|

Management Radial Scar

© AGO e. V.
in der DGGG e.V.
sowie
in der DKG e.V.

Guidelines Breast
Version 2019.1

- “When RS (radial scar) is associated to atypia (such as flat epithelial atypia (FEA), atypical ductal (ADH), or lobular neoplasia (classical LN)), management can the same as recommended in cases of atypia alone.

Follow-up Imaging for Women Age 50–69 Years with B3-Lesions

© AGO e. V.
in der DGGG e.V.
sowie
in der DKG e.V.

Guidelines Breast
Version 2019.1

- **FEA, non-atypical papilloma**

- Screening mammography

- **LIN**

- Mammography (12 months)

- **ADH**

- Mammography (12 months)
 - Women with LIN and ADH should be informed about their elevated risk of breast cancer

| | Oxford | | |
|--|--------|----|-----|
| | LoE | GR | AGO |
| Screening mammography | 5 | C | ++ |
| Mammography (12 months) | 3a | C | ++ |
| Mammography (12 months) | 3a | C | ++ |
| Women with LIN and ADH should be informed about their elevated risk of breast cancer | 3a | C | ++ |

Medical Prevention for Lesions with Uncertain Biological Behavior (incl. LIN, ADH)



© AGO e. V.
in der DGGG e.V.
sowie
in der DKG e.V.

Guidelines Breast
Version 2019.1

- Tamoxifen for women > 35 years – Risk reduction of invasive BrCa and DCIS
- Aromatase inhibitors (Exemestan, Anastrozole) for postmenopausal women
- Raloxifen for postmenopausal women – Risk reduction of invasive BrCa only

| | Oxford | | |
|--|--------|----|------|
| | LoE | GR | AGO |
| | 1a | A | + |
| | 1b | A | +/- |
| | 1b | A | +/-* |

Medical prevention should only be offered after individual and comprehensive counseling; the overall benefit is dependent on classification, age and pre-existing conditions that may influence the occurrence of side effects.

* Risk situation as defined in NSABP P1-trial (1,66% in 5 years)

Prevention for Lesions with Uncertain Biological Behavior (Tamoxifen)

NSABP-P2 Study, STAR trial 2006

| | Placebo Rate / 1000 WE | Tamoxifen Rate / 1000 WE | RR | 95% CI |
|----------------------------------|------------------------|--------------------------|-------------|------------------|
| All women | 6.29 | 3.59 | 0.57 | 0.46-0.70 |
| ± LCIS | 5.93 | 3.41 | 0.58 | 0.46-0.72 |
| + LIN | 11.70 | 6.27 | 0.54 | 0.27-1.02 |
| w/o ADH | 5.87 | 3.69 | 0.63 | 0.50-0.78 |
| + ADH | 10.42 | 2.55 | 0.25 | 0.10-0.52 |
| 5-year-risk <2% | 4.77 | 3.18 | 0.67 | 0.43-1.01 |
| 5-year-risk > 5% | 11.98 | 5.15 | 0.43 | 0.28-0.64 |
| Relative 1. grade | 6.47 | 3.48 | 0.54 | 0.34-0.83 |
| > 3 relatives 1. grade | 11.24 | 5.48 | 0.49 | 0.16-1.34 |
| Fractures | 2.88 | 1.97 | 0.91 | 0.51-0.92 |
| Endometrial cancer | 0.68 | 2.24 | 3.28 | 1.87-6.03 |

Should only be offered to women with enhanced breast cancer risk (Gail $\geq 1,66\%$):

- LIN , with ADH
- Family history of breast cancer

Should not be offered to women:

- With moderate risk and > 50 year of age
- With enhanced risk for thrombembolism

Prevention for Lesions with Uncertain Biological Behavior (Tamoxifen, Side Effects)

**Risks and Benefits with long-term Tamoxifen use compared with placebo:
results from the IBIS-I Trial 96 months median follow-up
(Cuzick J et al J Natl Cancer Inst 2007:272-282)**

| Incidence | RR | 95% CI | AR je 1000* | NNT / NNH** |
|--|------|-----------|-------------|-------------|
| Breast cancer | 0.73 | 0.58-0.91 | 15 | 68 |
| Invasive carcinoma | 0.74 | 0.58-0.94 | 12 | 81 |
| Thrombembolism | 1.72 | 1.27-2.36 | 14 | 73 |
| Deep vein thrombosis leg | 1.84 | 1.21-2.82 | 9 | 115 |
| Headache | 0.93 | 0.87-0.99 | 25 | 39 |
| Gynecological-/ vasom- otoric symptoms | 1.08 | 1.06-1.10 | 64 | 16 |
| Chest pain | 0.77 | 0.70-0.84 | 58 | 17 |

AR*:Absolute risk per 1000 women. **NNT/NNH**** = number needed to treat or number needed to harm

Data shown are statistically significant associations for a follow-up-period of 96 month.

Calculations by the authors of the guideline. Visvanathan K et al. JCO 2009;27:3235-3258.

Prevention for Lesions with Uncertain Biological Behavior (Raloxifen)

NSABP-P2 Study, STAR Trial 2006

| | Tamoxifen: Rate / 1000 WE | Raloxifen Rate / 1000 WE | RR | 95% CI |
|-----------|------------------------------|-----------------------------|------|-----------|
| All women | 4.30 | 4.41 | 1.02 | 0.82-1.28 |
| ± LIN | 3.76 | 3.89 | 1.03 | 0.81-1.33 |
| + LIN | 9.83 | 9.61 | 0.98 | 0.58-1.63 |
| ± ADH | 4.06 | 4.03 | 0.99 | 0.76-1.28 |
| + ADH | 5.21 | 5.81 | 1.12 | 0.72-1.74 |

Should only be offered to women with enhanced breast cancer risk :

- (Gail \geq 1,66%) or postmenopausal

Should not be offered to women:

- With moderate risk > 50 year of age
- With enhanced risk for thromboembolism

Prevention for Lesions with Uncertain Biological Behavior (Aromatase Inhibitors)

© AGO e. V.
in der DGGG e.V.
sowie
in der DKG e.V.

Guidelines Breast
Version 2019.1

Inclusion criteria:

Results for prior ALH, ADH, LCIS (HR AI vs Plac):

■ IBIS.2:

- Prior ADH, ALH, or LCIS
Anastrozole: 154 (8,0%);
Placebo: 190 (9,7%)

- Yes (7J-MaCa-Risiko 12,1%):
HR 0,31 (0,12–0,84)
- No (7J-MCa-Risiko 4,9%):
HR 0,52 (0,31–0,78)

■ MAP.3:

- Prior ADH, ALH, or LCIS:
Exemestane: 185 (8,1%);
Placebo: 188 (8,3%)

- Yes: HR=0,61 (0,20–1,82)
- No: HR=0,26 (0,11–0,64)